

# Strategies for Managing the Difficult Capsulorhexis

Understanding the problem is the key to avoiding complications.

**BY DAVID F. CHANG, MD**

**T**here are four general conditions that increase the risk of a radial capsulorhexis tear: poor visibility, eye movement, chamber shallowing, and increased capsular elasticity. These situations may arise either because of the ocular anatomy or due to poor surgical technique.

## **POOR VISIBILITY**

A good red reflex and visibility are important in order to manipulate the flap and monitor the direction of the tear as it develops. A surgeon's delayed recognition of a peripherally escaping tear may preclude any chance to redirect it in time.

Ocular causes of a poor red reflex include tear film debris, decreased corneal clarity, small pupils, anterior cortical opacity (anterior spokes or white cataract), nuclear opacity (brunescence), and vitreous opacities such as asteroid hyalosis or hemorrhage. Errors in surgical technique may also compromise visibility. Excessive drying can cloud the corneal epithelium. Poor irrigation fluid runoff may submerge the cornea. Clumsy instrument maneuvers might create corneal striae or displace the globe out of optimal microscope alignment. Finally, excessive downward pressure from the capsulotomy needle's tip will penetrate and stir up the epinucleus. This can cause focal loss of the red reflex right at the area where the flap inserts.

With challenging cases, surgeons must pay greater attention than usual to sharp focus, a clear corneal tear film, and positioning the eye so as to optimize the red reflex. The surgeon should increase the microscope zoom

if necessary. Furthermore, a surgeon should consider trypan blue dye whenever he anticipates difficulty with visualizing the anterior capsule. He can apply dye even after he initiates the capsulotomy, because trypan blue preferentially stains the capsule but not the cortex.

## **EYE MOVEMENT**

The potential for eye movement is characteristic of topical anesthesia or an unintentional consequence of a poor regional block. A sudden unanticipated head or eye movement may cause a peripheral radial tear. Patients must be cooperative enough to have surgery under topical anesthesia, and using appropriate levels of sedation and communication should enhance their cooperation. Fixation is improved by avoiding excessive microscope light intensity, which can induce squeezing. During the capsulotomy, the cornea should be moistened in a way so as to avoid startling the patient or surgeon. One way to eliminate the need for an assistant to manually wet the cornea during surgery is to lubricate it in the following manner. The surgeon first smears a few streaks of a dispersive ophthalmic viscosurgical device (OVD) such as Viscoat (Alcon Laboratories, Inc., Fort Worth, TX), Amvisc Plus (Bausch & Lomb, Rochester, NY), or Occucoat (Bausch & Lomb) onto the corneal surface. Adding several drops of balanced salt solution will create an even, but viscous wetting layer that will resist evaporation and provide superb clarity.

## **ANTERIOR CHAMBER SHALLOWING**

The natural anterior convexity of the equatorial lens tends to steer any capsular tear toward the periphery.

The shallower the chamber is, the more convex the anterior capsule becomes, and the more the tear tends to run radially “downhill.” The direction of the tear is most easily controlled if the anterior capsular surface is flattened.

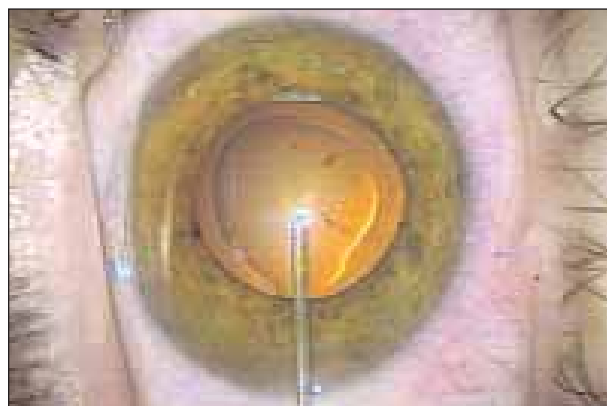A shallow anterior chamber may be the natural result of a small globe, narrow angles, or an intumescent lens. Severe zonular laxity may result in an unexpectedly shallow chamber despite a normal axial length. A common cause of anterior capsular convexity is intraoperative shallowing of the anterior chamber due to escape of fluid or OVD through the wound. Excessive instrument pressure on the posterior incision lip will “burp” the chamber through a momentary wound gape, and the surgeon should interrupt the capsulotomy step to inject more OVD.

Because it creates more of a mass effect, a maximally cohesive OVD is better able to flatten the anterior capsular convexity when compared with a dispersive OVD. The latter better resists being burped out through the incision however. The soft-shell technique originated by Steve A. Arshinoff, MD, FRCSC, from the University of Toronto combines the complementary advantages of each OVD by placing the cohesive agent directly over the anterior capsule and blocking the incision with the dispersive OVD<sup>1</sup> (Figure 1). Healon 5 (Advanced Medical Optics, Inc., Santa Ana, CA) is a maximally cohesive and viscoadaptive OVD that combines both of these desirable characteristics in a single agent.<sup>2</sup>

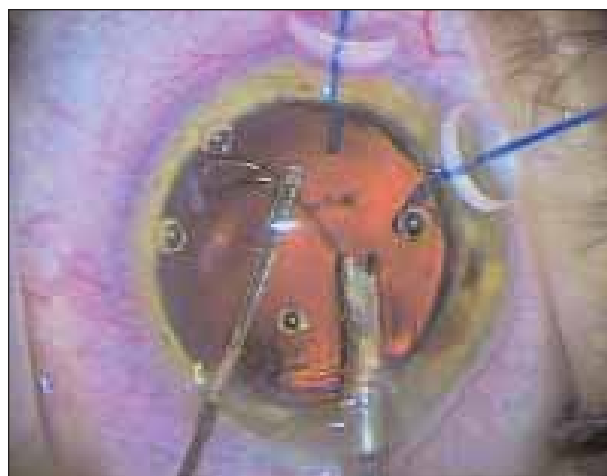
### CAPSULAR ELASTICITY AND PSEUDOELASTICITY

The more elastic a material is, the more difficult it is to control how it tears. As an example, latex is more difficult to tear accurately than paper. As one attempts to tear an elastic material, it first stretches before abruptly splitting. Because of the rebound energy, the resulting tear is overly rapid and tends to slingshot away from, rather than toward, the grasping instrument. Because pediatric anterior capsules are very thin and elastic, the flap tends to spiral outward and is very difficult to control.<sup>3</sup> Similarly, the adult posterior capsule has less tensile strength, and it is thinner and more elastic than the anterior capsule. It behaves more like the pediatric anterior capsule, and accomplishing a posterior capsulorhexis is more challenging for this reason.

Lacking sufficient circumferential tension, a capsule that is not taut will also exhibit elastic behavior. As the surgeon pulls on the anterior capsular flap, the peripheral capsule should be immobile if he is to control the precise direction of the tear. This situation occurs if the zonules are intact, but weak zonules give rise to a condition that I call *capsular pseudoelasticity*,<sup>4,5</sup> where the anterior capsule is of normal



**Figure 1.** Soft-shell technique. After first injecting the dispersive OVD (Viscoat), the cohesive OVD (Provisc), is injected over the convex anterior capsule. This step pushes the dispersive OVD into the cornea and against the inner incision wall.



**Figure 2.** Mackool capsular retractors (Impex Surgical, Staten Island, NY) are long enough to be able to hook the capsulorhexis edge and yet support the equatorial capsule.

adult thickness but behaves as though it is more lax and pliant due to insufficient zonular traction. Because the peripheral capsule will move along with, and in the same direction the flap is being pulled, the tear is difficult to control and will tend to slingshot radially. Poor surgical technique whereby the capsular flap is allowed to become too long can also create pseudoelasticity. The farther the grasping point of the capsular forceps is from the tearing point, the more pliant the flap becomes, and the more difficult it is to direct the tear. If the tear tends to spiral radially outward, the surgeon must regrasp the flap closer to the leading edge of the tear.

In higher-risk cases, I consider the capsulorhexis to be a “zonular stress test,” because the first indication of how

weak the zonules are becomes evident during this step. If the anterior capsule is very lax, the capsulotomy needle's tip will tend to dimple and indent it, rather than immediately puncture it. Next, as the surgeon tugs the capsular flap, the peripheral lens capsule is likely to stretch and move along with the flap toward the forceps. With extreme zonular weakness, the entire lens may start to move with the capsular forceps. The surgeon needs to take great care to avoid outward spiraling of the tear. In addition to using capsular forceps to regrasp the flap more frequently, employing the tear recovery technique originated by Brian Little, MD, from the Royal Free Hospital NHS Trust, in London, United Kingdom, is invaluable in these situations (see *Retrieval Maneuver for CCC Tear-Out* on page 70).

“In higher-risk cases, I consider the capsulorhexis to be a ‘zonular stress test,’ because the first indication of how weak the zonules are becomes evident during this step.”

If pseudoelasticity is severe, the surgeon can use iris hooks or specially designed capsular retractors to help anchor the bag during the capsulorhexis step.<sup>6</sup> Richard Mackool, MD, Director of The Mackool Eye Institute and Laser Center in Astoria, New York, has designed self-retaining retractors that are elongated enough to hook a small-diameter capsulorhexis from the limbus<sup>7</sup> (Figure 2). After completing several clock hours of the capsulorhexis, one or more capsular retractors can be placed. These retractors stabilize the bag and provide helpful countertraction against the tugging flap. Care must be taken to avoid placing too much tension on the capsular edge with the retractors, as this force alone can extend the tear uncontrollably. A surgeon can use the capsular tension segments created by Ike Ahmed MD, FRCSC, from the University of Toronto and the University of Utah in Salt Lake City, in a similar manner. A surgeon should never insert a capsular tension ring before completing the capsulorhexis, however, because the expansive force of the ring will extend the tear. If the pupil is of borderline size, enlarge its diameter with iris retractors. Optimal visualization of the peripheral capsular region is of far greater importance here than with a routine case.

Opinions differ regarding the target diameter of the capsulorhexis in eyes with loose zonules. A larger-diameter capsulorhexis will make nuclear and cortical removal much easier, but it is much harder to complete in eyes with capsular pseudoelasticity. With weakened zonules, the

more peripherally the tear advances, the more it wants to veer radially outward, and the more difficult it is to rescue the flap. In comparison, a smaller-diameter capsulorhexis is easier to control. It increases the margin for error by allowing more time to recognize and rescue a peripherally escaping tear. Although a small-diameter capsulotomy may somewhat hinder the subsequent surgical steps, it is far preferable to having a torn capsular edge, particularly when other risk factors are present.

For this reason, I believe that one should always aim for a smaller-diameter capsulorhexis in the presence of significant zonular laxity. Successful completion of a continuous circumferential edge is more important than attaining the optimal size. The surgeon must mentally visualize its diameter during nuclear emulsification, however, so as not to tear it with the chopper shaft or phaco tip. Bimanual instrumentation is superior for cortical cleanup in loose capsular bags and greatly improves subincisional access through a small capsulorhexis. Modern injectors facilitate implantation of foldable IOLs through a small capsular opening. Finally, the surgeon should secondarily enlarge the capsulorhexis after the IOL and capsular tension ring are safely implanted, as discussed in another article in which I discuss in *Pearls for Sizing the Capsulorhexis* on page 55.

## CONCLUSION

In summary, achieving an intact capsulorhexis is crucial to the safety of the cataract procedure. To maximize the odds of success, the surgeon needs to make the diameter smaller when he encounters difficulty. Given the long-term importance of having a properly sized capsular opening, the surgeon should secondarily enlarge a small capsulorhexis following IOL insertion when the surgical conditions are more favorable. ■

David F. Chang, MD, is Clinical Professor at the University of California, San Francisco, and is in private practice in Los Altos, California. He is a consultant for Advanced Medical Optics, Inc., Alcon Laboratories, Inc., and Visiogen. Dr. Chang may be reached at (650) 948-9123; dceye@earthlink.net.



1. Arshinoff SA. Dispersive-cohesive viscoelastic soft shell technique. *J Cataract Refract Surg.* 1999;25:167-173.
2. Arshinoff SA. Using BSS with viscoadaptives in the ultimate soft-shell technique. *J Cataract Refract Surg.* 2002;28:1509-1514.
3. Saini JS, Jain AK, Sukhija F, et al. Anterior and posterior capsulorhexis in pediatric cataract surgery with or without trypan blue dye. Randomized prospective clinical study. *J Cataract Refract Surg.* 2003;29:1733-1737.
4. Chang DF. Phacoemulsification in high-risk cases. In: Wallace RB, ed. *Multifocal IOLs and Refractive Cataract Surgery.* Chapter 11. Thorofare, NJ: Slack; 2001.
5. Chang DF. Strategies for the difficult capsulorhexis. In: Chang DF, ed. *Phaco Chop.* Chapter 12. Thorofare, NJ: Slack; 2004.
6. Lee V, Bloom P. Microhook capsule stabilization for phacoemulsification in eyes with pseudoexfoliation-syndrome-induced lens instability. *J Cataract Refract Surg.* 1999; 25:1567-1570.
7. Mackool RJ. Capsule stabilization for phacoemulsification (letter). *J Cataract Refract Surg* 2000;26:629.