

Pearls for Sizing the Capsulorhexis

Surgeons share their own techniques.

BY DAVID F. CHANG, MD; STEVEN DEWEY, MD; RICHARD TIPPERMAN, MD;
AND R. BRUCE WALLACE III, MD

DAVID F. CHANG, MD

The capsulorhexis is generally considered the most important step in cataract surgery. A continuous curvilinear capsulorhexis (CCC) provides numerous surgical advantages,¹ and a continuous curvilinear capsular edge reduces the chance of a capsular tear occurring during surgery. Like an elastic waistband, the capsulorhexis will stretch—rather than tear—in response to surgical forces. A continuous edge is necessary to perform cortical cleaving hydrodissection, and it facilitates cortical cleanup as well as the placement of both haptics into the capsular bag. It also converts the anterior capsule into a contingency platform for IOL support should the posterior capsular tear.

The postoperative advantages of a properly sized capsulorhexis are equally important. As the capsular bag contracts, it prevents pea-podding (ie, the escape of either haptic).^{2,3} Asymmetric capsular forces resulting from an eccentric CCC can cause delayed optic decentration. Continuous circumferential overlap of the IOL's optic edge will produce a capsular shrink-wrap effect, whereby the posterior capsule is kinked by the optic edge—a major factor in the prevention of posterior capsular opacification (PCO).^{4,5} This overlap will also lessen any edge dysphotopsias as it opacifies over time. Finally, such continuous overlap of the optic's edge is the only way to attain consistency in the axial IOL position from case to case. Being able to accurately predict this effective lens position is a critical factor in calculating the proper IOL power for emmetropia.

It follows that a capsulorhexis with a diameter extending beyond the optic edge in some or all areas loses these advantages. Posterior lens epithelial cell migration will occur in any region where the posterior capsule is not kinked by the optic's edge.⁵ Over time, slight optic decentration may result from asymmetric capsular contractile forces. Finally, as the posterior capsule tenses postoperatively, the optic may be slightly more anteriorly displaced wherever it is not restrained by a taut capsulorhexis edge, resulting in a myopic shift.

What are the disadvantages of a capsulorhexis with a diameter that is too small? In addition to impeding surgical steps such as the removal of subincisional cortex, a small-diameter CCC may also create postoperative problems. The increased load of lens epithelial cells on the back of the anterior capsule can increase inflammation, cause anterior capsular fibrosis and opacification, and result in excessive contraction of the capsulorhexis and capsular bag,⁶⁻⁸ leading to zonular damage or dehiscence and optic decentration.^{9,10} With sufficiently weakened zonules, visually significant capsulophimosis or subluxation of the bag-IOL complex can occur.^{7,11} Finally, excessive anterior capsular opacification can impair visualization of the peripheral retina.

Given the importance of obtaining a proper capsulorhexis diameter, it is ironic that this is one of the only cataract surgical steps that technology has not yet improved. We continue to use a low-tech, manual method to perform the tear with a needle and/or

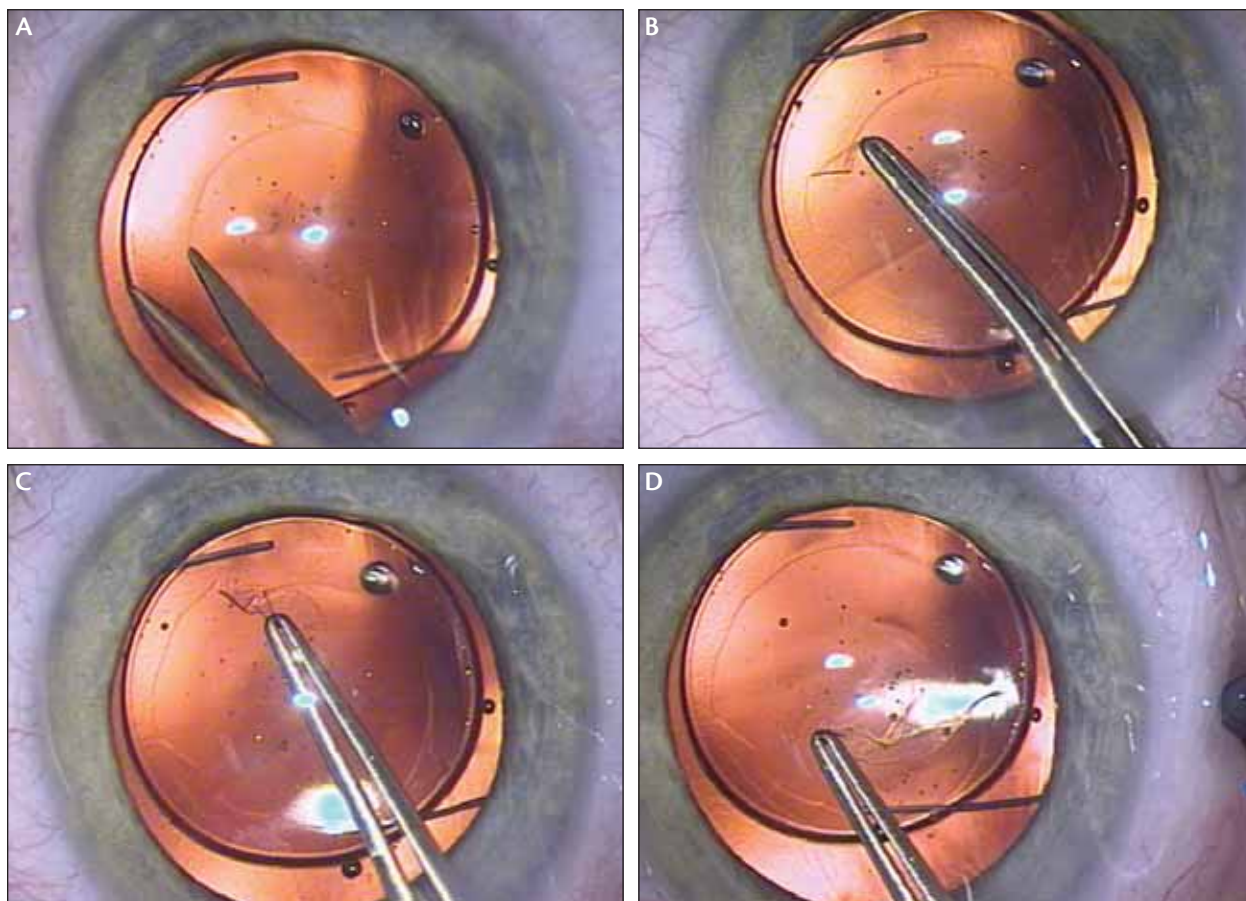


Figure 1. A small-diameter capsulorhexis is enlarged with forceps after creating a new flap with an oblique microscissors cut (A–D).

forceps. The intended diameter is estimated visually. Individual variability in anterior segment and pupil diameter and corneal magnification make it difficult to precisely size the capsulorhexis. Parallax occurring with movement of the globe makes it difficult to judge the symmetry and centration of the evolving capsulotomy.

My personal solution for sizing the capsulorhexis is to plan on performing it in two stages when necessary (Figure 1). As I make the primary capsulorhexis, I try to err on the small side, because the diameter can always be enlarged, but not reduced. I take a moment to assess the appropriateness of the CCC diameter after IOL implantation. Frequently, the size and centration are fine, but it is surprising how often the CCC is slightly eccentric to the center of the optic. Sometimes, a perfectly round CCC becomes ovoid following implantation due to the directional stretch of the stiff three-piece haptics. This is a sign of zonular laxity and insufficient centrifugal tension in the areas perpendicular to the haptic axis.

In either situation, or if the overall diameter is too small, I enlarge the capsulorhexis by making an oblique

cut with a pair of scissors and grasping the resulting flap with capsular forceps (Figure 1A and B). The cut should be oblique, rather than radial, so that the resulting flap is more inclined to tear in a circumferential direction. The flap is then maneuvered with capsular forceps under a generous amount of ophthalmic viscosurgical device. Curved Uthoff-Gills capsulotomy scissors with blunt tips (Katena K4-5126; Katena Products, Inc., Denville, NJ) have the perfect shape for creating an initial curved cut to either side of the phaco incision. If the pupil is small enough to conceal the optic's edge, it can be locally retracted with a Lester hook (Figure 2). In some cases, I only trim a part of the remaining anterior capsular rim where it is excessively wide. Other times, I re-tear the entire 360° circumference of the opening (Figure 1).

Executing the second-stage enlargement may be easier than the primary capsulotomy for several reasons. Following removal of the cataract, the red reflex is improved, and there is no convexity to the anterior capsule to promote radial extension of the tear. The optic provides a perfect visual template for resizing the CCC's

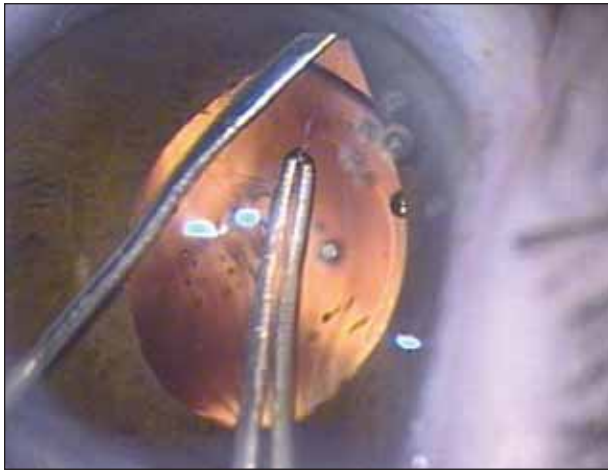


Figure 2. A Lester hook is used to retract the iris to better view the IOL's optic edge.

diameter. Finally, in cases of weak zonules, the presence of the three-piece haptics or a capsular tension ring increases outward tension on the capsular bag, improving control over the direction of the tear. Should the tear escape peripherally, it is reassuring that no subsequent surgical steps would extend the tear posteriorly. The IOL should not be rotated in this situation, however, for this reason.

Although in most cases, enlargement of a smallish capsulorhexis is not absolutely necessary, I encourage the mastery of this technique. With multifocal IOLs, achieving a symmetric capsulorhexis that completely overlaps the optic's edge is particularly important. There is even less margin for CCC diameter error with accommodating IOLs such as the Crystalens (Eyeonics, Inc., Aliso Viejo, CA). With dynamic accommodating designs such as the Visiogen Synchrony ICL (Visiogen, Inc., Irvine, CA), if the CCC's diameter is too large, it may allow the anterior optic to partially protrude through the capsulotomy. Too small of an opening, however, may cause capsulophimosis or excessive capsular fibrosis that may strain the zonules, stiffen the bag, and incapacitate the accommodative mechanism. Initially erring on the small side, with the option to enlarge it when and where necessary, is the only 100% reliable way I have to attain a perfectly sized capsulorhexis diameter.

Finally, comfort with this maneuver is important if there is difficulty steering the flap during the primary capsulorhexis. Whether the cause is poor visibility, patient movement, a shallow chamber, or weak zonules, the surgeon can make a smaller diameter opening to increase control and to better avoid a peripheral extension. The diameter can be secondarily enlarged after the IOL has been implanted.

STEVEN DEWEY, MD

A properly sized capsulorhexis is an absolute must for standardizing the results of cataract surgery. In routine cases, overlapping the edge of the optic by 0.5 to 1 mm will result in a consistent lens position from case to case. It also has the benefit of driving the sharp posterior edge of an IOL into the posterior capsule and reducing the potential for PCO. In less routine cases, an intact capsulorhexis allows for optic capture to secure the IOL, even if the posterior capsule is completely absent.

Sizing the capsulorhexis can be challenging. The variability of pupil dilation and corneal diameter may make it difficult to consistently create the proper opening, and therefore, the easiest method is the most direct. Prior to loading the IOL into the insertion device, simply hold the lens over the surgical field and mentally establish the relative size of the optic to the size of the eye.

Several techniques have been developed to gauge the proper capsulorhexis size. R. Bruce Wallace III, MD, of Louisiana, advocates the use of an optical zone marker to effectively provide a size guide (*see Dr. Wallace's description on the following page*). Barry S. Seibel, MD, of Los Angeles, created capsulorhexis forceps with a millimeter marker on the shaft as an intraocular gauge. This product is manufactured by Microsurgical Technology (Redmond, WA) and easily works with either a standard or bimanual incision.

Instrumentation inherently creates different-sized openings, and this appears to be related to the tangential forces applied as the capsule is torn. A bent needle, which holds the flap closer to the tear, creates a smaller capsular opening. Forceps, which grasp the capsule farther from the tear, will generally create a larger opening.

Although I prefer a 0.5- to 1.0-mm overlap of the anterior capsule on the optic, more overlap is also acceptable, as long as the surgical technique can accommodate removing the nucleus and cortex through a smaller opening. To keep my capsulorhexis size smaller, I generally prefer a dispersive ophthalmic viscosurgical device to flatten the capsule, and I use a bent needle. In cases of poor visualization or loose zonules, the forceps provide extra control. Of course, a larger capsulorhexis is appropriate when the situation warrants, such as when dealing with a very dense cataract or in cases of zonular laxity where an endocapsular approach should be abandoned.

RICHARD TIPPERMAN, MD

Creating an appropriately sized capsulorhexis is critical for achieving excellent clinical results with presbyopia-correcting IOLs. Regardless of the IOL, a consistent capsulorhexis size will improve predictability of the IOL power calculation.

A specific capsulorhexis size is ideal for maximizing an optic's exposure, centration, and movement with an accommodating IOL. If the capsulorhexis is too small with a true multifocal IOL (ie, simultaneous vision), the amount of light able to travel through the peripheral portion of the IOL is restricted, thereby limiting the light energy transmitted from this portion of the lens. A variety of techniques that aim to create a specific-sized capsulorhexis have been described. The following is an approach that has worked well in my clinical practice.

At the start of surgery, I ask the patient to fixate on the microscope light, and I try to center a 6-mm radial keratotomy optical zone marker on the reflection from the microscope light. Placing the optical zone in this fashion creates a 6-mm circular indentation on the patient's cornea that is roughly centered on his visual axis. I then begin the tear of my capsulorhexis and bring it out until it is in line with the inner edge of the mark from the optical zone marker.

At this point, if the pupil is round and symmetric, I no longer need to shift my focus between the anterior capsule and the corneal dome where the optical zone marker is visible. I simply mentally note the distance between the capsulorhexis' edge and the iris sphincter and then complete the tear for the full 360°. I try to maintain this constant distance for the entire capsulotomy.

This is a simple technique using readily available instrumentation that provides for a consistent capsulorhexis size. Surgeons often find that shifting their fixation from the corneal dome to the anterior capsule while trying to bring the tear around can be cumbersome at best. At worst, this maneuver will lead to unpredictable sizing or difficulty with completing the capsulorhexis. Using the corneal marker to create a landmark for the peripheral border of the tear and then completing the capsulorhexis with a different constant landmark in the anterior capsular plane (ie, pupillary margin) makes consistent sizing of the capsulorhexis much simpler.

R. BRUCE WALLACE III, MD

A well-centered and properly sized anterior capsulotomy plays an important role in achieving successful visual outcomes after cataract or lens-based refractive surgery. Many studies have credited the reduced rate of PCO to an anterior capsular overlap of the periphery of the IOL's optic.¹²⁻¹⁴ Sequestering the optic also improves implant power prediction with more reliable lens constants for IOL calculation formulas, and creating an anterior capsular shelf allows for easier insertion of an IOL in the ciliary sulcus, if indicated.¹²

In 2003, I described a method to consistently create a well-centered and properly sized capsulorhexis.¹² After placing the capsulotomy diameter mark, the surgeon

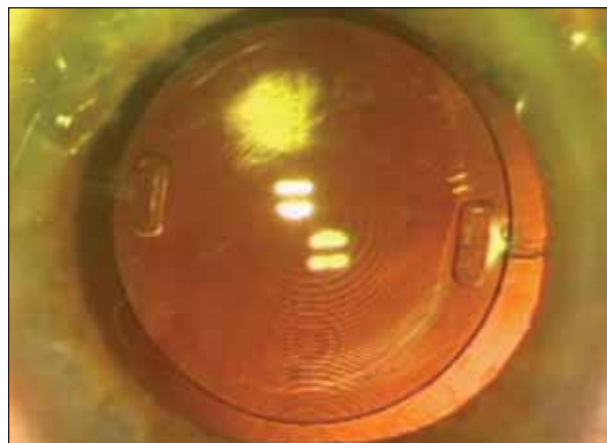


Figure 3. With a 6-mm-optic IOL, making a central 5.0- to 5.5-mm anterior capsulotomy results in a 360° capsular overlap.

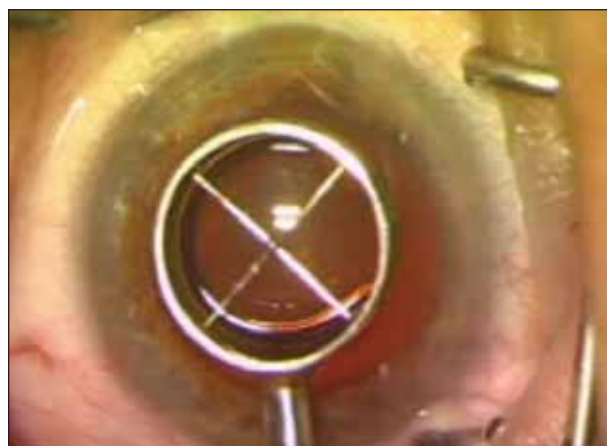

Figure 4. A capsulotomy diameter mark is placed on the central cornea with a 6-mm optical zone marker.

has a visual template to guide the location and proper diameter of the capsulotomy (Warren E. Hill, MD, oral communication).¹⁵ For instance, if a 6-mm optic IOL is to be implanted, making a central 5.0- to 5.5-mm anterior capsulotomy will result in a 360° capsular overlap of the peripheral IOL (Figure 3).

At the beginning of the procedure, the surgeon places a 6-mm optical zone mark on the central cornea (Figures 4 and 5). I have learned that parallax from the surgical microscope can cause minor decentration of the capsulotomy. A rule of thumb is to shift the mark slightly to the left for a right-eye-dominant surgeon and to the right for left-eye dominance. During the capsulotomy, bring the initiated flap to just inside the cornea mark, and slowly complete the capsulotomy. Always stay just inside the circular mark on the cornea. Due to corneal magnification, the resulting capsulotomy should measure 5.0 to 5.5 mm. An easy way to gauge

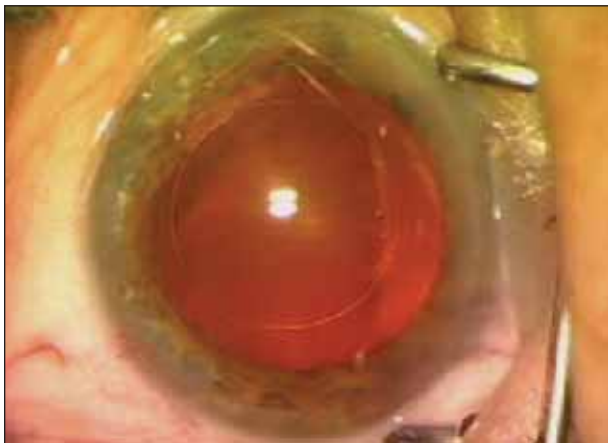

Figure 5. The resulting capsulotomy diameter mark on the cornea serves as a guide for creating the capsulorhexis.

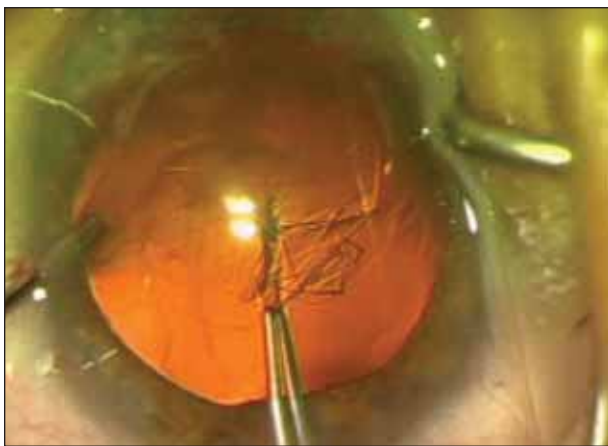


Figure 6. The tear is made just inside the capsular diameter mark with modified Utrata forceps.

the IOL's centration and size is to evaluate the capsular coverage of the 6-mm IOL optic after implantation.

Because I routinely utilize topical anesthesia for lens surgery, I like to stabilize the globe when performing these measures. I place a blunt-tip cyclodialysis in the sideport incision before making a tear in the central capsule with a bent 25-gauge needle. I guide the tear temporally to the edge of the capsulotomy diameter mark and complete the circular capsulotomy with modified Utrata forceps (Figure 6). Sharp-tipped capsular forceps may be used for the entire procedure; however, they need to be replaced when the tips become dull. Replacing the autoclavable stainless steel 25-gauge bent needle is less costly.

Refractive cataract surgery and lens-based refractive surgery have moved to center stage. These procedures will continue to grow in popularity with aging baby boomers. Any step we can take to improve IOL power

accuracy and reduce complications such as PCO will help us become more successful in achieving the desired results for our patients. ■

David F. Chang, MD, is Clinical Professor at the University of California, San Francisco, and is in private practice in Los Altos, California. He is a consultant for Advanced Medical Optics, Inc., Alcon Laboratories, Inc., and Visiogen, Inc. Dr. Chang may be reached at (650) 948-9123; dceye@earthlink.net.



Steven Dewey, MD, is in private practice with Colorado Springs Health Partners in Colorado. He has no financial interest in the products or companies mentioned herein. Dr. Dewey may be reached at (719) 475-7700; sdewey@cshp.net.



Richard Tipperman, MD, is a member of the active teaching staff at Wills Eye Hospital in Philadelphia. He is a consultant for Alcon Laboratories, Inc. Dr. Tipperman may be reached at (610) 664-8880; rtipperman@mindspring.com.



R. Bruce Wallace III, MD, is Medical Director of Wallace Eye Surgery in Alexandria, Louisiana, Clinical Professor of Ophthalmology at the LSU School of Medicine, and Assistant Clinical Professor of Ophthalmology at the Tulane School of Medicine in New Orleans. He is a consultant for Advanced Medical Optics, Inc. Dr. Wallace may be reached at (318) 448-4488; rbw123@aol.com.



- Gimbel HV, Neuhann T. Development, advantages, and methods of the continuous circular capsulorhexis technique. *J Cataract Refract Surg.* 1990;16:31-37.
- Assia EI, Legler UF, Merrill C, et al. Clinicopathologic study of the effect of radial tears and loop fixation on intraocular lens decentration. *Ophthalmology.* 1993;100:153-158.
- Ram J, Apple DJ, Peng Q, et al. Update on fixation of rigid and foldable posterior chamber intraocular lenses. Part I: Elimination of fixation-induced decentration to achieve precise optical correction and visual rehabilitation. *Ophthalmology.* 1999;106:883-890.
- Ram J, Pandey SK, Apple DJ, et al. Effect of in-the-bag intraocular lens fixation on the prevention of posterior capsule opacification. *J Cataract Refract Surg.* 2001;27:367-370.
- Nishi O, Nishi K, Wickstrom K. Preventing lens epithelial cell migration using intraocular lenses with sharp rectangular edges. *J Cataract Refract Surg.* 2000;26:1543-1549.
- Hansen SO, Crandall AS, Olson RJ. Progressive constriction of the anterior capsular opening following intact capsulorhexis. *J Cataract Refract Surg.* 1993;19:77-82.
- Davison JA. Capsule contraction syndrome. *J Cataract Refract Surg.* 1993;19:582-589.
- Joo CK, Shin JA, Kim JH. Capsular opening contraction after continuous curvilinear capsulorhexis and intraocular lens implantation. *J Cataract Refract Surg.* 1996;22:585-590.
- Hayashi K, Hayashi H, Nakao F, Hayashi F. Anterior capsule contraction and intraocular lens decentration and tilt after hydrogel lens implantation. *Br J Ophthalmol.* 2001;85:1294-1297.
- Hayashi H, Hayashi K, Nakao F, Hayashi F. Anterior capsule contraction and intraocular lens dislocation in eyes with pseudoexfoliation syndrome. *Br J Ophthalmol.* 1998;82:1429-1432.
- Jahan FS, Marmalis N, Crandall AS. Spontaneous late dislocation of intraocular lens within the capsular bag in pseudoexfoliation patients. *Ophthalmology.* 2001;108:1727-1731.
- Ravalico G, Tognetto D, Palomba MA, et al. Capsulorhexis size and posterior capsule opacification. *J Cataract Refract Surg.* 1996;22:98-103.
- Hollick EJ, Spalton DJ, Meacock WR. The effect of capsulorhexis size on posterior capsular opacification: one-year results of a randomized prospective trial. *Am J Ophthalmol.* 1999;128:271-279.
- Apple DJ, Peng Q, Visessook N, et al. Eradication of posterior capsule opacification: documentation of a marked decrease in Nd:YAG laser posterior capsulotomy rates noted in an analysis of 5416 pseudophakic human eyes obtained postmortem. *Ophthalmology.* 2001;108:505-518.
- Wallace RB. Capsulotomy diameter mark. *J Cataract Refract Surg.* 2003;29:1866-1868.