

Flexible Strategies for Managing IFIS

Because the manifestations of IFIS are variable, surgeons must be prepared to use a variety of techniques to reduce the chance of complications.

BY DAVID ALLEN, BSc, FRCOPHTH

Since Chang and Campbell alerted us to the association between intraoperative floppy iris syndrome (IFIS) and the use of tamsulosin by patients,¹ we surgeons have become much more aware of the syndrome. When reading this report, many of us realized that IFIS must have been the cause of problems in “that difficult patient a few weeks ago.”

Now that we have a name for the syndrome and are familiar with its signs, we can recognize IFIS in patients who take other medications, particularly alpha-1 adrenoceptor-blocking agents (eg, doxazosin, alfuzosin, terazosin). Other drugs may also be implicated, however. Pringle and Packard reported IFIS in a patient using the antipsychotic medication zuclopenthixol.² I have also seen IFIS in a patient taking a different antipsychotic drug,

risperidone. This pharmaceutical agent is designed as a selective monoaminergic antagonist, but it is also said to have alpha adrenoceptor-blocking properties. Finally, as well as sometimes observing IFIS in diabetic patients, I also see the syndrome in patients not taking any medication at all (Figure 1), although I have not taken a meticulous history of past medication to identify the possible previous use of alpha-1 antagonists. It is important, therefore, that we be aware of the problems posed by IFIS and the potential options for their management.

VARIABLE PRESENTATION

In the second half of 2005, I performed cataract surgery on 30 eyes of 20 patients who were taking tamsulosin.³ I did not change my preoperative protocol or add any in-

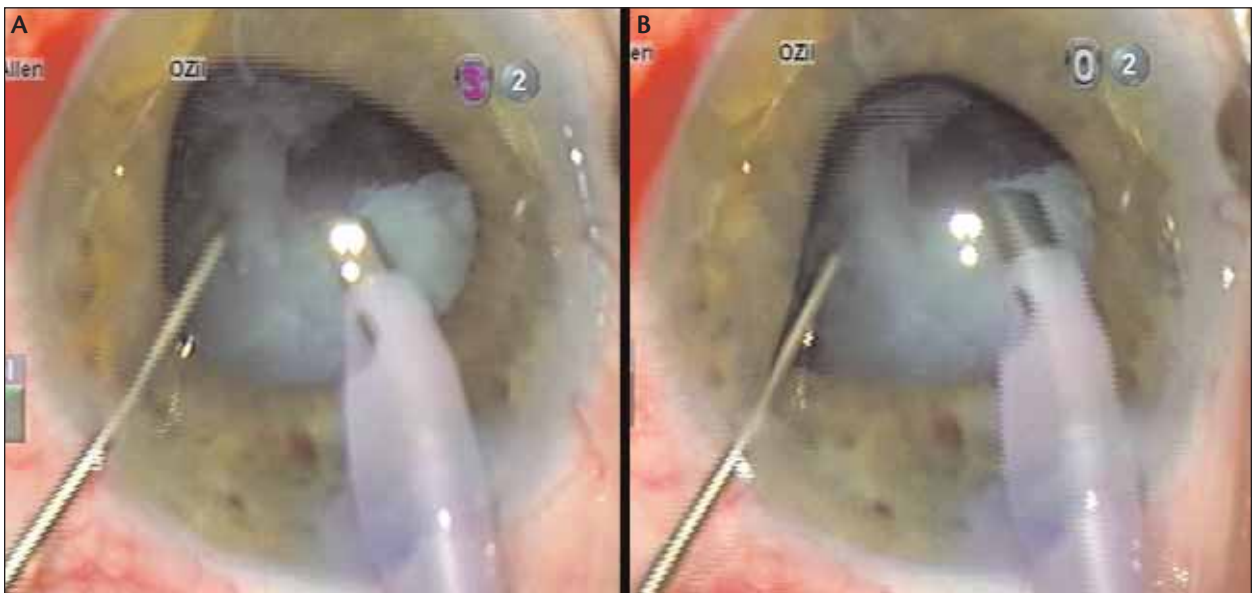


Figure 1. These single frames, 0.2 seconds apart, were grabbed from a surgical video of the eye of a patient taking no systemic medication (A and B). The volatile behavior of the iris is clearly visible (the pupil has also constricted since the start of the surgery).

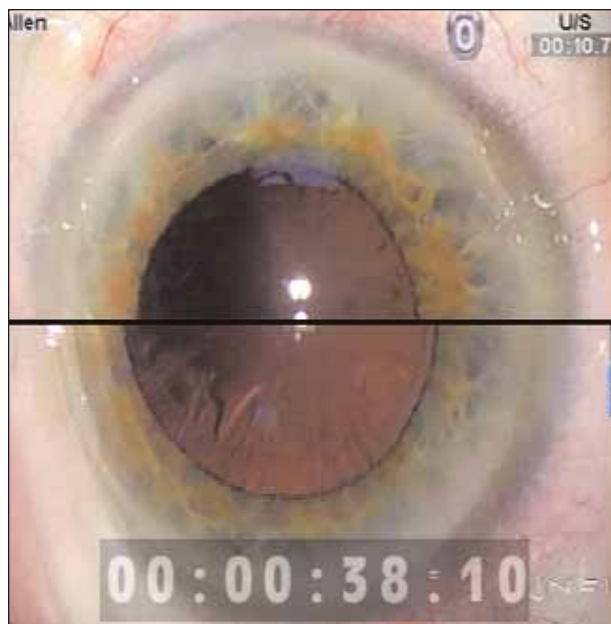


Figure 2. This pupil shrank during phacoemulsification (top), and the dilatation 38 seconds after the intracameral injection of phenylephrine (bottom) is clear.

tervention so that I could observe the natural range of IFIS' presentations in this group of patients. The syndrome's manifestations varied greatly, and the behavior of the irides of the same patient's two eyes often differed markedly. In short, approximately half of the patients had a well-dilated pupil at the outset of surgery, but about half of those pupils subsequently constricted during surgery. A further 38% of the 30 eyes had moderately dilated (4.5 to 5.5mm) pupils, and only 9% had small pupils. This sort of variety demands flexibility on the part of the surgeon managing eyes with IFIS.

ALPHA AGONISTS

Shortly after the description of the IFIS problem, Richard Packard, MD, FRCS, FRCOphth, of Windsor, UK, and I independently but simultaneously noted the beneficial effect of intracameral phenylephrine. Mr. Packard's experience was published first.⁴ In a formal study of 30 eyes by Sridhar Manvikar, DO, FRCS, and me, we found that, if a pupil constricted during surgery to an extent that threatened to cause problems, it would redilate to its original size following the injection of phenylephrine intracamerally.⁵

We also noted a beneficial effect in eyes that showed a tendency for the iris to prolapse to/through the main and/or sideport incision. Under these circumstances, further constriction may be expected, and significant pigmentary shedding can occur. The use of intracameral

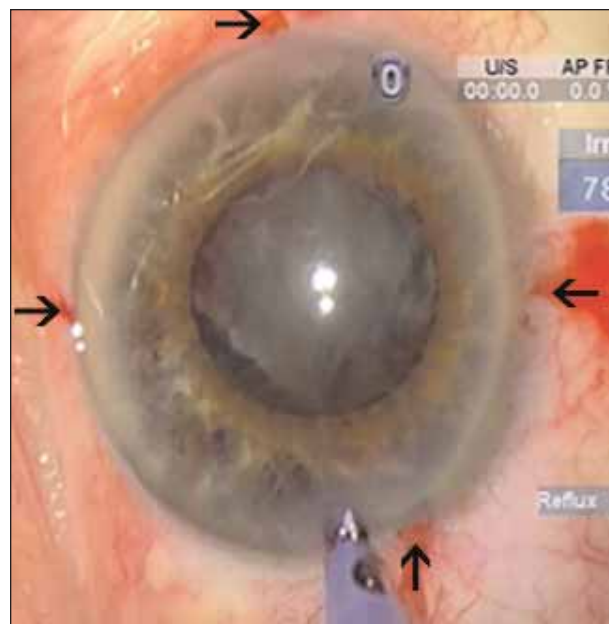


Figure 3. Four incisions have been made with an MVR blade to allow the placement of iris hooks, should they be necessary if the pupil constricts further.

phenylephrine stabilized the iris, probably by "toning" it to a degree, and the tendency to prolapse completely disappeared. In eyes that had small pupils, and in some of those with medium pupils, we used intracameral phenylephrine at the outset of surgery. That sometimes caused the pupil to dilate further. In all cases, however, the drug again stabilized the iris, and no further constriction occurred during surgery.

The intracameral administration of phenylephrine is off label in the US and in Europe. Many surgeons, however, have routinely used the drug as part of an intracameral, mydriatic "cocktail" in cataract surgery. Lundberg and Behndig⁶ reported no statistically significant difference in endothelial cell loss following the intracameral administration of phenylephrine compared with traditional topical agents. In a letter to the *Journal of Cataract & Refractive Surgery*, Soong and colleagues reported an absence of adverse cardiovascular events in a group of patients intensively monitored after the use of the same cocktail.⁷

US surgeons have reported similarly beneficial effects from the use of intracameral epinephrine (in addition to the small dose normally added to irrigating solutions) (see the article on this topic by Joel Shugar, MD, on page 72), but there were no peer-reviewed reports of its benefit at the time of this writing. Until a direct injection of alpha agonists into the anterior chamber is licensed and approved for routine use, I suggest the following strategy.

A FLEXIBLE STRATEGY

Tip No. 1: Alert the Staff

We should emphasize the need for a thorough drug history for each patient so that individuals using alpha-1 antagonists are identified before surgery. The staff should be aware of any scheduling requirements we may have for potentially complex cases. Ophthalmologists may wish to consider referring patients with a history of tamsulosin use (the commonest cause of IFIS) to surgeons with particular experience in this area. Regardless, we should be alert to the possibility of IFIS in every patient.

Tip No. 2: Lower the Settings

I would suggest using low flow and vacuum settings to reduce the amount of fluid flow and turbulence in the anterior chamber. This strategy does not guarantee an absence of problems, however.⁸ Because of a lack of repulsion of nuclear material, the new torsional phaco mode possible with the Ozil handpiece on the Infiniti Vision System (Alcon Laboratories, Inc., Forth Worth, TX) allows very efficient surgery with reduced flow and vacuum.⁹

“The threshold for an intracameral injection of an alpha agonist into the anterior chamber is lower with moderately versus fully dilated pupils.”

Tip No. 3: Use an Alpha Agonist as Appropriate

If the pupil is well dilated, I begin surgery as normal. In my experience, approximately half of these patients will have uneventful surgery. If their pupil constricts during surgery or tends to prolapse, I have my staff prepare intracameral phenylephrine or epinephrine.

My staff empties one “minim” (a preservative-free, single-use device [Laboratoires Chauvin SA, Montpellier, France; not available in the US]) into the barrel of a 2-mL syringe and mixes it with 1.0 to 1.5mL of balanced salt solution. I will inject up to 1mL of the prepared intracameral alpha agonist into the anterior chamber and will wait as long as 30 seconds for the maximal effect (Figure 2). This technique can be helpful even at the end of nuclear removal to allow safe epinuclear or cortical cleanup.

For a partially dilated (4.5 to 5.5mm) pupil, I would consider injecting a prepared alpha agonist at the outset of surgery. One may also wish to use a highly viscous ophthalmic viscosurgical device (OVD) such as Healon GV (Advanced Medical Optics, Inc., Santa Ana, CA) or Microvisc Plus (Bohus Biotech, Stromstad, Sweden; not available in the US) or a viscoadaptive OVD such as

Healon 5 (Advanced Medical Optics, Inc.) or Discovisc (Alcon Laboratories, Inc.) to help dilate the pupil further. In addition, some ophthalmologists favor the use of OVDs as a means of tamponading or compartmentalizing the iris during surgery. The threshold for an intracameral injection of an alpha agonist into the anterior chamber is lower with moderately versus fully dilated pupils.

For a small (≤ 4 mm) pupil, I recommend the intracameral injection of an alpha agonist at the start of surgery. Depending on the surgeon’s level of experience in dealing with miotic pupils, he may wish to consider using mechanical pupil expanders. My only experience is with flexible iris hooks. The incisions for their use may be made at the beginning of the surgery in the event of later problems (Figure 3). It is particularly helpful to position the hooks in a diamond configuration rather than the original square pattern. The hook located under the main phaco incision keeps that part of the iris well retracted and prevents prolapse. It also ensures ample access to the nucleus for the phaco needle.

SUMMARY

IFIS is a potentially serious problem if not recognized and managed appropriately. Our awareness of the syndrome’s signs is important. The approach described herein helps to minimize problems. Additional interventions such as mechanical pupillary dilatation or the routine injection of unlicensed products should be used only when necessary. ■

David Allen, BSc, FRCOphth, is a consultant ophthalmologist specializing in cataract surgery at Sunderland Eye Infirmary in the UK. He has received reimbursement for travel and lodging expenses from Alcon Laboratories, Inc., but stated that he holds no direct financial interest in the products or companies mentioned herein. Mr. Allen may be reached at +44 191 5699071; david.allen@chs.northy.nhs.uk.



1. Chang DF, Campbell JR. Intraoperative floppy iris syndrome associated with tamsulosin (Flomax). *J Cataract Refract Surg.* 2005;31:664-673.
2. Pringle E, Packard R. Antipsychotic agent as an etiologic agent of IFIS. *J Cataract Refract Surg.* 2005;31:2240-2241.
3. Manvikar SR, Allen D. Systematic approach to cataract surgery in patients taking tamsulosin. Paper presented at: The ASCRS/ASOA Symposium on Cataract, IOL and Refractive Surgery; March 19, 2006; San Francisco, CA.
4. Gurbaxani A, Packard R. Intracameral phenylephrine to prevent floppy iris syndrome during cataract surgery in patients on tamsulosin. *Eye.* 2005 Nov 11; [E-pub ahead of print].
5. Manvikar S, Allen D. A progressive approach to managing cataract surgery in patients taking tamsulosin. *J Cataract Refract Surg.* In press.
6. Lundberg B, Behndig A. Intracameral mydriatics in phacoemulsification cataract surgery. *J Cataract Refract Surg.* 2003;29:2366-2371.
7. Soong T, Soultanidis M, Clauoué C, et al. Safety of intracameral mydriasis in phacoemulsification cataract surgery. *J Cataract Refract Surg.* 2006;32:375-376.
8. Osher RH. Association between IFIS and Flomax. *J Cataract Refract Surg.* 2006;32:547.
9. Allen D. Efficient surgery with a new torsional phaco mode. Paper presented at: The ASCRS/ASOA Symposium on Cataract, IOL and Refractive Surgery; March 18, 2006; San Francisco, CA.