

Managing IFIS With Iris Retractors

These devices likely offer the most consistently reliable approach.

BY DAVID F. CHANG, MD

Intraoperative floppy iris syndrome (IFIS) is most commonly associated with systemic alpha-1 blockers such as tamsulosin (Flomax; Boehringer Ingelheim Pharmaceuticals, Inc., Ridgefield, CT), doxazosin (Cardura; Pfizer Inc., New York, NY), terazosin (Hytrin; Abbott Laboratories Inc., North Chicago, IL), and alfuzosin (Uroxatral; Sanofi-Aventis, Paris, France). A triad of intraoperative signs—iris billowing and floppiness, iris prolapse to the main and side incisions, and progressive miosis—characterizes IFIS and increases the risk of surgical complications when surgeons do not anticipate the condition.¹

IFIS may be categorized as mild (ample pupillary dilation plus some floppiness of the iris without prolapse or constriction), moderate (some tendency for iris prolapse and some constriction of a moderately dilated pupil), or severe (classic triad and poor preoperative dilation). Of all of the systemic alpha-1 blockers, tamsulosin has the strongest tendency to produce IFIS. The difference may relate to the much higher affinity and specificity of this drug for the alpha-1A receptor subtype present in the iris dilator smooth muscle.²

Because the severity of IFIS varies significantly among patients (and even between the eyes of the same patient), it is difficult to conclude whether one surgical technique is superior to another. By gaining experience with several different approaches, surgeons will invariably develop personal preferences. This article focuses on iris retractors.

COMPARING APPROACHES

Stopping tamsulosin preoperatively is of unpredictable and questionable value, as there are many documented cases of IFIS' occurring up to several years following the drug's cessation.^{1,2} Preoperatively administered atropine drops (eg, 1% b.i.d. for 3 days before surgery) will maximize cycloplegia. This strategy alone is

often insufficient, however, for moderate-to-severe IFIS. Intracameral epinephrine or other alpha agonists can increase the iris' rigidity and prevent the pupil's constriction. Partial-thickness sphincterotomies and mechanical stretching of the pupil are ineffective for IFIS and should be avoided, because they may instead exacerbate the prolapse and miosis.¹

As general principles, one must be attentive to their incision's proper construction, perform hydrodissection more gently and slowly than usual, and use lower I/A flow parameters if possible. Of all the ophthalmic viscosurgical devices (OVDs), Healon 5 (Advanced Medical Optics, Inc., Santa Ana, CA) has particular utility in eyes

TABLE 1. OVERCOMING HISTORICAL OBJECTIONS TO IRIS RETRACTORS

Objection	Rebuttal
Too costly	Reusable iris hooks are very cost effective
Time consuming to place	Stiffer 4–0 polypropylene hooks are much easier to handle and manipulate than 6–0 nylon
Iris sphincter will be torn and damaged	With IFIS, the sphincter is elastic rather than fibrotic. Maximal stretching can therefore occur without excessive trauma to the sphincter muscle
Iris is tented up in front of the phaco tip	The diamond configuration avoids this problem and the associated iris chafing
Insufficient surgical exposure	The diamond configuration and the ability to maximally stretch an IFIS pupil provide superb visualization and exposure

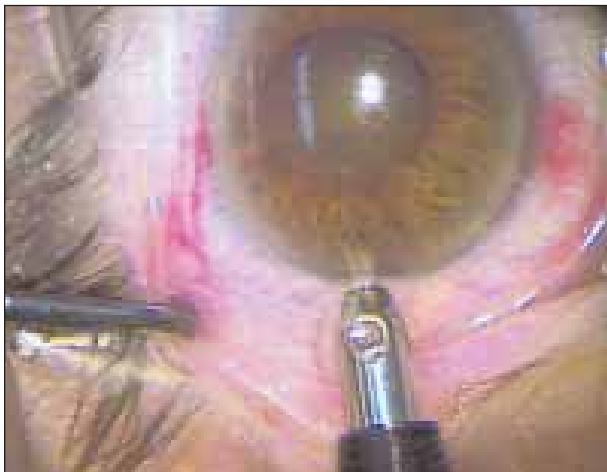

Figure 1. The author makes a separate limbal stab incision just behind the temporal clear corneal incision.

with IFIS.^{2,3} Its maximally cohesive properties are ideal for viscomydriasis and for blocking iris prolapse. To prevent the OVD's premature aspiration, lower flow and vacuum rates (eg, < 26mL/min and < 175 to 200mmHg) are recommended. Even then, supplemental re-injections become necessary as the OVD is eventually aspirated. There is a learning curve for mastering the unique viscoadaptive properties of Healon 5, and this IFIS strategy is less suitable if high vacuum settings are needed for a dense nucleus.

Disposable pupil expansion rings are costly but 100% effective. Both the Morcher 5S Pupil Ring (Morcher GmbH, Stuttgart, Germany; distributed by FCI Ophthalmics, Inc., Marshfield Hills, MA) and the Perfect Pupil (Milvella Ltd., Sydney, Australia) are grooved PMMA rings that are threaded alongside the pupillary margin using metal injectors. The surgeon uses a disposable plastic injector to insert the Graether silicone pupil expansion ring (Eagle Vision, Inc., Memphis, TN). All of these rings are more difficult to position if the anterior chamber is shallow or if the pupil is less than 4mm wide. On the other hand, if the pupil is initially too large, the smaller-diameter Morcher and Graether designs will be unable to engage the margin of the iris.

Iris retractors are probably the single most consistent approach that works equally well across the wide range of both IFIS' severity and surgeons' experience (Table 1). They provide another completely reliable strategy for pupillary expansion that can be used regardless of how small or large the starting diameter of the pupil is.

TECHNIQUE

I prefer reusable 4–0 polypropylene retractors (available from Katena Products, Inc., Denville, NJ, and FCI

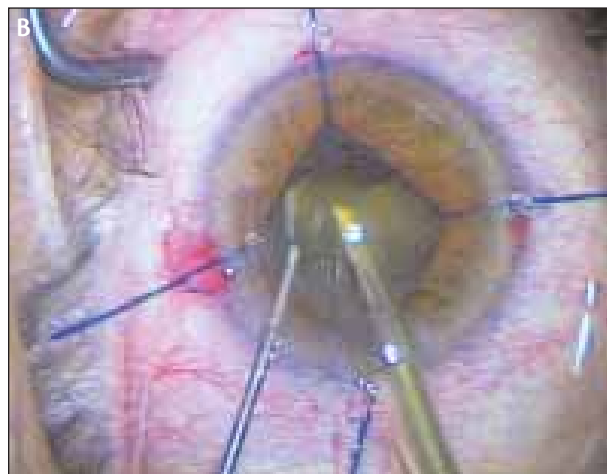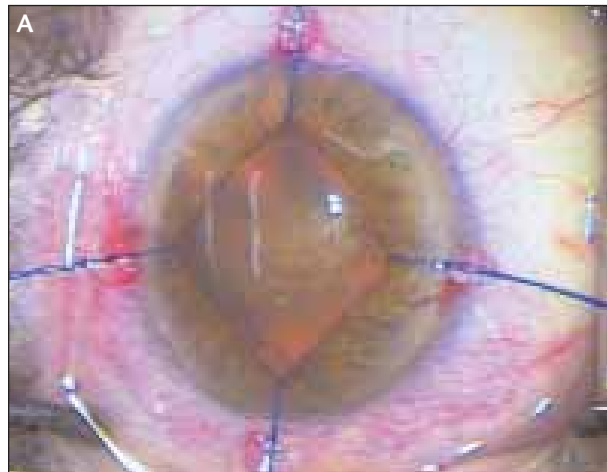


Figure 2. The author places reusable 4–0 polypropylene iris retractors (Katena Products, Inc.) in a diamond configuration, as described by Oetting and Omphroy⁴ (A). A subincisional retractor pulls the iris down and away from the phaco tip while maximizing surgical exposure (B).

Ophthalmics, Inc.) to disposable 6–0 nylon retractors (available from Alcon Laboratories, Inc., Fort Worth, TX). At 0.15mm in diameter, the 4–0 retractors are the same size and stiffness as the polypropylene haptic of an IOL. The added stiffness and rigidity, when compared with 6–0 nylon retractors, make 4–0 retractors more durable and easier to manipulate. The 4–0 polypropylene hooks can be autoclaved repeatedly, which makes them more cost effective than their disposable counterparts.

Before initiating the capsulorhexis, I make 1-mm limbal paracenteses in each quadrant, including a separate stab incision just posterior to the temporal clear corneal incision (Figures 1 and 2). In this way, the phaco tip passes through a separate incision directly alongside and above the track for the subincisional retractor. Placing the hooks in this diamond configuration has several advan-

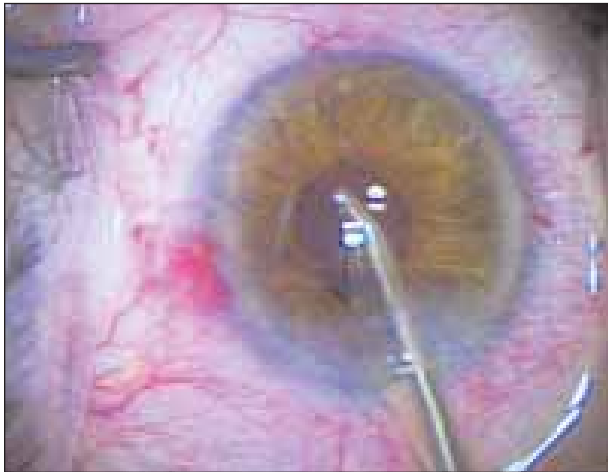


Figure 3. During the removal of viscoelastic and following the withdrawal of the retractors, the iris prolapses, and the pupil immediately constricts.

tages.⁴ The subincisional hook retracts the iris downward and out of the path of the phaco tip. This configuration also maximizes exposure directly in front of the phaco tip (Figure 2B). The paracentesis incisions may be made with any 1-mm wide diamond or metal blade.

“Overextension does not occur with the IFIS pupil, which is so elastic that it readily springs back to physiologic size.”

Iris retractors both enlarge and maintain a constant pupillary size throughout the course of surgery. They provide sufficient tension to the iris stroma so that no prolapse can occur. If the pupil is fibrotic, such as with chronic pilocarpine use or longstanding posterior synechiae, overstretching the iris can cause bleeding, tear the sphincter, and result in permanent mydriasis. Fortunately, overextension does not occur with the IFIS pupil, which is so elastic that it readily springs back to physiologic size despite being maximally stretched (Figure 3). Following the IOL's implantation, the iris retractors are removed, rinsed in balanced salt solution, and gently dabbed with an instrument wipe to remove any viscoelastic residue. They are then stored in the autoclavable storage container (Figure 4).

Like pupil expansion rings, iris retractors are much easier to insert prior to the initiation of the capsulorhexis. If the pupil dilates poorly in a patient taking tamsulosin, one should anticipate severe IFIS and consider using

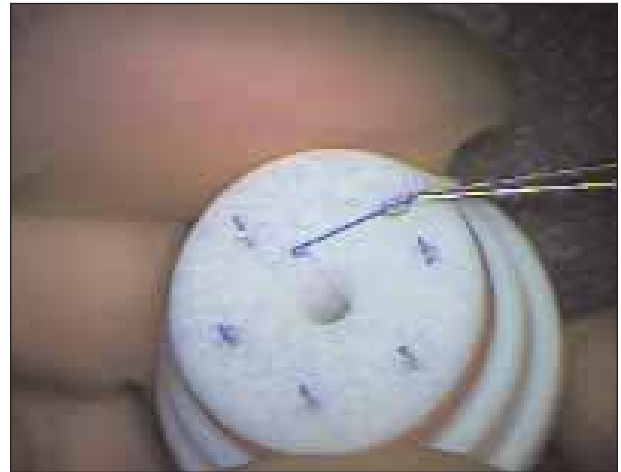

Figure 4. Sterilizing case for reusable iris retractors.

these mechanical devices. Often, however, the pupil dilates reasonably well, and it is not until after hydrodissection or during phacoemulsification that the prolapse and miosis occur. Healon 5 and intracameral epinephrine are excellent rescue techniques in this situation, where it is difficult to see the edge of the capsulorhexis. If one elects to insert iris retractors at this point, it is useful to lift the pupillary margin with a Lester manipulating hook (Katena Products, Inc.) to avoid engaging the capsulorhexis' margin with the retractors.

CONCLUSION

Eliciting a history of alpha-1 blocker use allows surgeons to anticipate IFIS and to employ a number of varied strategies, either alone or in combination. When I anticipate severe IFIS, such as when the pupil dilates poorly preoperatively, I employ iris retractors because they are 100% reliable in circumventing the problems of IFIS. I also tend to use these devices if there are other concurrent risk factors such as a brunescens lens, pseudoexfoliation, or weak zonules. ■

David F. Chang, MD, is Clinical Professor at the University of California, San Francisco, and is in private practice in Los Altos, California. He is a consultant for Advanced Medical Optics, Inc., and Alcon Laboratories, Inc., but acknowledged no financial interest in the products mentioned herein. Dr. Chang may be reached at (650) 948-9123; dceye@earthlink.net.



1. Chang DF, Campbell JR. Intraoperative floppy iris syndrome associated with tamsulosin (Flomax). *J Cataract Refract Surg.* 2005;31:664-673.
2. Chang DF. Intraoperative floppy iris syndrome. In: Agarwal A, ed. *Phaco Nightmares*. Thorofare, NJ: Slack, Inc. In press.
3. Arshinoff SA. Modified SST-USST for tamsulosin-associated intraocular floppy iris syndrome. *J Cataract Refract Surg.* 2006;32:559-561.
4. Oetting TA, Omphroy LC. Modified technique using flexible iris retractors in clear corneal surgery. *J Cataract Refract Surg.* 2002;28:596-598.