

# The Modified Use of OVDs for IFIS

Technical changes to the soft shell and ultimate soft shell techniques for eyes with floppy irides due to tamsulosin.

BY STEVE A. ARSHINOFF, MD, FRCSC

Ophthalmic viscosurgical devices (OVDs) are unique tools in anterior segment surgery. The ophthalmologist can select OVDs based upon their classification<sup>1</sup> to create a physical environment to facilitate the management of almost any surgical problem.<sup>2</sup> Best known and most frequently used are the soft shell and ultimate soft shell techniques, for which variations to manage specific problems have been described.<sup>3-9</sup>

Chang and Campbell<sup>10</sup> brought to ophthalmic surgeons' attention intraoperative floppy iris syndrome (IFIS), associated with the systemic administration of the alpha-A1 adrenoceptor antagonist tamsulosin (Flomax; Boehringer Ingelheim Pharmaceuticals, Inc., Ridgefield, CT) for benign prostatic hypertrophy. The condition presents a challenging and ever more common surgical problem to cataract surgeons. Chang and Campbell described the clinical, intraoperative, diagnostic triad of (1) fluttering and billowing of the iris stroma caused by ordinary intraocular fluid currents, (2) a propensity for iris prolapse through the phaco and/or sideport incisions, and (3) the progressive constriction of the pupil during surgery. These signs are accompanied by suboptimal pupillary dilation in response to preoperative mydriatic protocols. In addition, pupillary

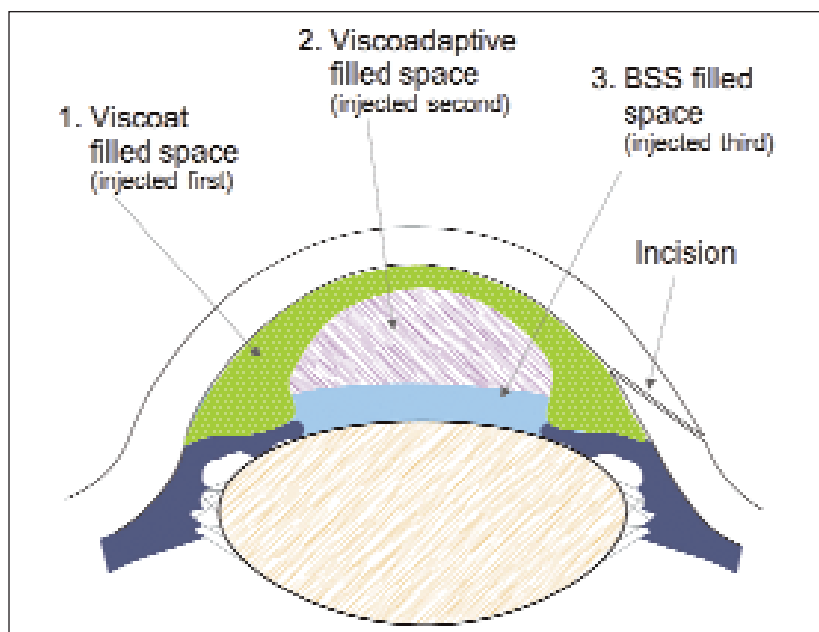


Figure 1. During IFIS SST-USST, the clear corneal incision is as long as reasonably possible so that, when the surgeon imagines depressing the cornea down to the level of the iris, the internal corneal incision is slightly central to the margin of the iris. As a result, iris prolapse is considerably less likely, and balanced salt solution may exit the eye easily without disturbing the OVD shell. After injecting Viscoat followed by Healon 5 and then balanced salt solution, the surgeon creates the capsulorhexis with a bent 27-gauge needle and keeps it smaller than the pupil. (Reprinted from Arshinoff SA. Modified SST-USST for tamsulosin-associated intraocular floppy-iris syndrome. *J Cataract Refract Surg.* 2006;32:559-561 with permission from the ASCRS and ESCRS.)

stretching techniques are ineffective due to the floppy, easily stretched nature of the pupillary margin, instead of the fibrosis seen in other cases of pupillary miosis refractory to protocols for dilation.

The degree of IFIS varies considerably among patients

taking similar doses of tamsulosin for about the same time. Chang and Campbell recommended the intraoperative use of iris hooks or other mechanical devices for pupillary dilation. They noted, however, that a failure to recognize IFIS before the performance of the capsulorhexis might make the use of these instruments difficult. Although they stated that they found Healon 5 (Advanced Medical Optics, Inc., Santa Ana, CA) to be useful in IFIS, Chang and Campbell did not mention the use of more elaborate, multiple-OVD techniques. The approach described herein, which I call *IFIS SST-USST*, follows directly from soft shell and ultimate soft shell methodology.<sup>11</sup>

“I try to lengthen the tunnel such that the internal corneal entry is slightly central to the pupillary margin, no matter how small the pupil is.”

## METHODS AND RESULTS

Illustrated schematically in Figure 1, the IFIS SST-USST consists of sequential steps to prevent expected problems before they occur. First, I make very tight incisions. Incisional leakage encourages the floppy iris to prolapse through the main and sideport incisions. I make a 1-mm sideport incision with the Arshinoff sideport diamond knife (Diamond Surgical Products, Thornville, OH).

I leave 1% nonpreserved Xylocaine (Astrazeneca LP, Wilmington, DE), intracamerally injected through the sideport, in the eye for at least 1 minute before proceeding. Doing so slightly improves pupillary dilation.

When fashioning the primary clear corneal phaco incision, I try to lengthen the tunnel such that the internal corneal entry is slightly central to the pupillary margin, no matter how small the pupil is. The pupils in severe IFIS cases are almost always 5 to 6mm in diameter, regardless of how many dilating drops they have received. These pupils also tend to constrict as surgery progresses.

I fill the anterior chamber to approximately 75% to 80% with Viscoat (Alcon Laboratories, Inc., Fort Worth, TX) via the phaco incision while making sure the OVD covers the peripheral iris. Next, I inject Healon 5 onto the surface of the anterior lens capsule, into the center of the anterior chamber, so that it pushes the Viscoat upward and outward until the pupil stops dilating. It is important that the boundary of the Healon 5/Viscoat

be at the pupillary margin. It will later serve as a boundary to fracture, and the OVDs will help to keep the iris stable and the pupil dilated throughout surgery. At this point, the anterior chamber should be more than 90% full of OVDs, and the eye should feel slightly firm. This step is a variation of the soft shell technique.

I then slowly inject balanced salt solution or some of the nonpreserved lidocaine (preferable because it will continue to enhance pupillary dilation) under the layer of Healon 5, on the surface of the lens capsule. I place the cannula's tip at the very center of the lenticular surface, from which the OVD soft shell becomes elevated. It also creates an aqueous pocket confined to the lenticular surface. This step is a variation of the ultimate soft shell technique, and it reduces the chance of aspirating the Healon 5 with the phaco or I/A tip.

Using a bent needle, I perform a routine capsulorhexis that begins at the center of the lens. I keep the diameter of the capsulorhexis smaller than that of the pupil. This sizing will later act to confine fluid flow into an area smaller than the pupil, thus preventing turbulence from impacting the iris and the Viscoat layer, which would permit the pupil to constrict. I perform hydrodissection with very short pulses of balanced salt solution from a 10-mL syringe with a 27-gauge hockey stick cannula.

The careful execution of the aforementioned steps and the placement of the cannula should permit balanced salt solution to circulate around the lens and flow out of the eye, beneath the OVD shell, without disturbing it. If hydrodissection or a later step of the procedure removes part of the shell, the surgeon should reinject Healon 5 followed by balanced salt solution to reestablish the shell before proceeding.

The settings for the Infiniti Vision System (Alcon Laboratories, Inc.) or a similar peristaltic machine are adjusted to achieve low turbulence. I use a flow rate of  $\leq 20\text{mL/min}$ , vacuum of  $\leq 300\text{mmHg}$ , and a bottle height that is 75 to 80cm above the patient's eye. I employ a linear, continuously variable pulse mode, preferably including Ozil (Alcon Laboratories, Inc.). I use phaco slice and separate, but a similar chopping technique would also work. I make sure that the phaco tip remains beneath the capsulorhexis' edge in order to confine fluid flow to the capsular bag.<sup>12</sup> Aspiration should only be turned on when nuclear material is actively being aspirated in order to minimize disturbance of the shell.

The Healon 5 forms the rigid inferior surface of the OVD soft shell, while Viscoat tamponades the iris. As a result, the iris is completely stable throughout the proce-

ture. If the pupil begins to constrict excessively during surgery, it may be necessary to reinject Healon 5 followed by balanced salt solution below it. I/A may similarly be accomplished with lower flow and vacuum settings (only occasionally necessary). I implant the IOL using the ultimate soft shell technique.<sup>4</sup>

After the surgeon aspirates the OVD shell at the end of cataract surgery, the characteristic billowing and fluttering of the iris will be observable. Sometimes, it is helpful at the conclusion of the procedure to reinflate the anterior chamber through the primary phaco incision so that no iris tissue becomes trapped in the incision. I then inject 0.1mL of moxifloxacin 100µg in 0.1mL of balanced salt solution into the capsular bag via the sideport incision. Doing so pressurizes the eye and provides antibacterial prophylaxis.

## DISCUSSION

Phaco surgery is usually routine, but unusual environmental problems, such as that induced by tamsulosin, do occur. From a structural point of view, the difficulties presented by IFIS are not very different from those associated with absent zonules and prolapsing vitreous, frayed iris strands, or low endothelial cell counts. OVDs allow surgeons to achieve almost any desirable physical environment in the anterior chamber. The IFIS SST-USST is merely one example. A great advantage of this technique is that the surgeon may institute it safely and effectively at any time during the procedure, unlike mechanical pupil dilators.

It is important to understand how and why the IFIS SST-USST works in order to use the technique well. I use Viscoat for the peripheral OVD ring, because I think it is the best low-viscosity, dispersive OVD available. This type of OVD tends to be highly retentive despite the presence of moderate fluid turbulence.<sup>13</sup> The viscoadaptive central layer of Healon 5 adds a relatively rigid OVD roof above the surgical space and brings rigidity to the OVD structure that keeps the iris from moving and the Viscoat in place. The layer of balanced salt solution, just over the pupillary space, provides working room for balanced salt solution to circulate during phacoemulsification.

It is important that a viscoadaptive agent be present above the layer of balanced salt solution; excessive mixing would occur if Viscoat were used alone. If the phaco turbulence can be restricted to the capsular bag and this confined area above it, the Healon 5 will not be dragged into the phaco tip, and the OVD shell will remain intact throughout the case. The layer of balanced salt solution serves another purpose. When performing hydrodissection, the surgeon depresses the

posterior lip of the phaco incision somewhat until the easy egress of aqueous can be obtained from the layer of balanced salt solution, beneath the layer of Healon 5 without disturbing it. This technique helps to preserve the OVD shell. The rigid Healon 5 bridge is essential to allow IFIS cases to proceed smoothly, and the surgeon may have to reinject Healon 5 if the bridge is accidentally disturbed. ■

*The use of moxifloxacin described in this article is off label.*

*Steve A. Arshinoff, MD, FRCSC, is a partner at York Finch Eye Associates, Humber River Regional Hospital, and The University of Toronto. He has served as a paid consultant to a number of OVD manufacturers, including all of those for the products mentioned herein. Dr. Arshinoff may be reached at (416) 745-6969; saaeyes@idirect.com.*



1. Arshinoff SA, Jafari M. A new classification of ophthalmic viscosurgical devices (OVDs)—2005. *J Cataract Refract Surg.* 2005;31:2167-2171.
2. Arshinoff SA. Dispersive and cohesive viscoelastic materials in phacoemulsification. *Ophthalmic Pract.* 1995;13:98-104.
3. Arshinoff SA. Dispersive-cohesive viscoelastic soft shell technique. *J Cataract Refract Surg.* 1999;25:167-173.
4. Arshinoff SA. Using BSS with viscoadaptives in the ultimate soft-shell technique. *J Cataract Refract Surg.* 2002;28:1509-1514.
5. Arshinoff S. Using viscoelastics to solve problems in cataract surgery. Video presented at: The ASCRS/ASOA Symposium on Cataract, IOL and Refractive Surgery; April 16-22, 1998; San Diego, CA.
6. Arshinoff SA. Using viscoelastics to manage problems in cataract surgery. In: Fishkind WJ, ed. *Complications in Phacoemulsification: Avoidance, Recognition and Management.* Thieme: New York; 2002:182-193.
7. Arshinoff SA. The ultimate soft shell technique (USST) and Acrysof Monarch injector cartridges. Letter. *J Cataract Refract Surg.* 2004;30:1809-1810.
8. Arshinoff SA. USST and no cycloplegic drops before cataract surgery. Letter. *J Cataract Refract Surg.* 2004;30:941-942.
9. Arshinoff SA. Capsular dyes and the USST. Letter. *J Cataract Refract Surg.* 2005;31:259-260.
10. Chang DF, Campbell JR. Intraoperative floppy iris syndrome associated with tamsulosin. *J Cataract Refract Surg.* 2005;31:664-673.
11. Arshinoff SA. Modified SST-USST for tamsulosin-associated intraocular floppy-iris syndrome [published correction to title appears in *J Cataract Refract Surg.* 2006;32:1076]. *J Cataract Refract Surg.* 2006;32:559-561.
12. Arshinoff SA. Phaco slice and separate. *J Cataract Refract Surg.* 1999;25:474-478.
13. Arshinoff SA, Wong E. Understanding, retaining, and removing dispersive and pseudo-dispersive OVDs. *J Cataract Refract Surg.* 2003;29:2318-2323.