Epithelial Ingrowth After Hyperopic LASIK

BY STEPHEN F. BRINT, MD; RONALD R. KRUEGER, MD;
GEORGE TATE, JR, MD; AND STEVEN J. DELL, MD

CASE PRESENTATION

A 64-year-old male returns to your clinic 4 years after undergoing hyperopic LASIK with flaps made using the Moria CB 130 microkeratome (Moria, Antony, France). The original, uneventful laser ablation used a 10-Hz Visx Star S2 (Advanced Medical Optics, Inc.) and 6 X 9mm profile for the following treatments: +1.00 +0.50 X 167 = 20/20 OD and +1.25 +0.50 X 002 = 20/20 OS.

The patient's postoperative course was uneventful. He achieved satisfactory postoperative UCVA, including at intermediate distance, because the treatments targeted slight myopia in both eyes. His left eye was dominant.

Lost to follow-up until now, the patient presents with reduced vision at distance and intermediate distance. His UCVA measures 20/30-2 OD and 20/25-2 OS. Cycloplegic refraction yields -0.25 +1.00 X 178 = 20/20 OD and -0.25 +0.25 X 008 = 20/20-2.

Biomicroscopy reveals mild, asymptomatic blepharitis and two well-centered LASIK flaps with superior hinges. There is evidence in the patient's right eye, however, of a 1.25 X 3.00mm edge of epithelial ingrowth, which appears to be dormant and stable, from the 6- to the 4-o'clock position (Figures 1 and 2). Similarly, the patient's left eye exhibits minimal epithelial cysts of 0.2 X 0.2mm at the 6-o'clock position.

There is evidence of mild nuclear sclerotic changes that were not observed at his last visit. They do not appear to affect his vision. The fundus examination is normal.

The patient is mainly interested in options for improving his distance vision, although he has noticed a loss of near vision. The earlier hyperopic LASIK procedure left residual corneal thicknesses of 550µm OD and 540µm OS. Subtraction pachymetry of the intraoperative flap-thickness measurements reveals 145-µm flaps bilaterally.

What intervention would you suggest?

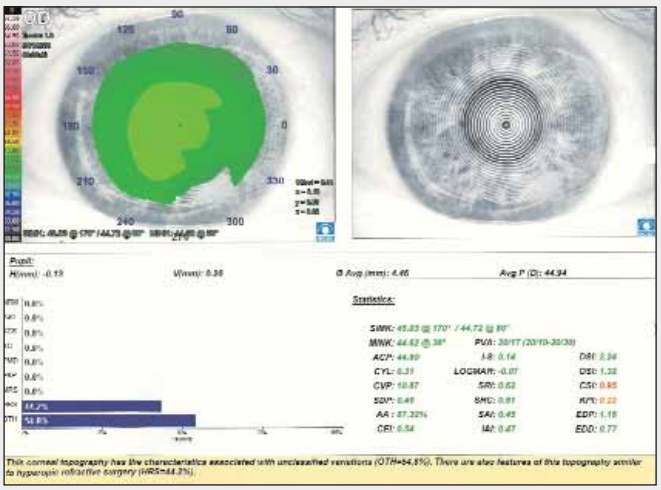

Figure 1. The Magellan Mapper (Nidek, Inc., Fremont, CA) topographically shows the induced cylinder in the patient's right eye. The Placido ring photograph (upper right) shows the associated irregularity from the epithelial ingrowth.

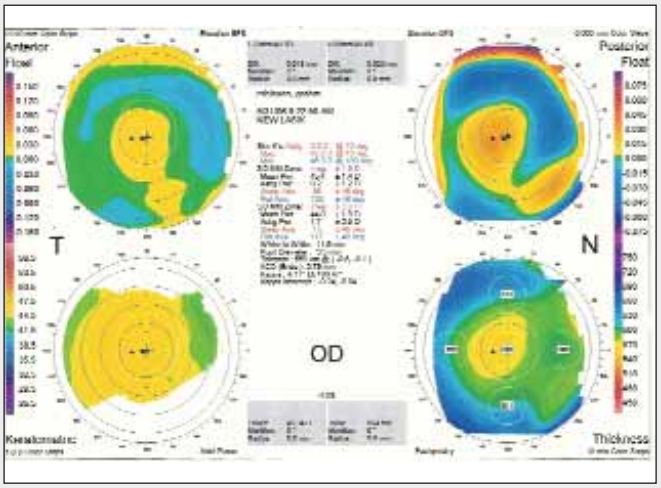

Figure 2. Orbscan topograhy shows the induced refractive changes related to the epithelial ingrowth.

STEPHEN F. BRINT, MD

This type of case presents rather often. My first choice would be to do nothing. I would describe the early lenticular changes to the patient. I would then explain that it would be better to wait to perform cataract surgery when appropriate and to use glasses as needed for distance and near for now. An option would be to try a contact lens in his right eye for intermediate distance with a target of -1.00D, because he has satisfactory distance UCVA in his dominant left eye and is emmetropic.

If the patient insisted on a surgical option, I would perform refractive lens exchange on his right eye with a target of -1.00D. I would first conduct a contact lens trial (described earlier) to make sure this treatment is what the patient really wants. I would calculate the IOL using the historical method, because the pre- and postoperative information is available and the original correction was rather small.

I would not recommend laser treatment, because lifting the flap could give rise to striae and more aggressive epithelial ingrowth when it is now quiescent. Surface ablation would be somewhat unpredictable and would risk poor surface healing, dry eye, and diffuse lamellar keratitis. The underlying lenticular changes are probably the real problem. I do not think, therefore, that laser treatment would satisfy the patient, and it would raise the possibility of corneal complications that the patient does not presently have.

RONALD R. KRUEGER, MD

Because the patient's left eye is dominant and has a nearly plano refraction, I would likely leave it alone and concentrate on the patient's right eye and its induced cylinder.

A remnant of epithelial ingrowth inferonasally seems to be contributing to the cylinder and aberrations. I would therefore suggest one of two options. If the epithelial ingrowth is elevating the flap's edge and has not eroded through, I would consider lifting the flap to scrape away the epithelium and consider a small laser enhancement. Alternatively, if the epithelial ingrowth has eroded through the flap so that mostly only a scar is left, then I would consider a PRK enhancement.The goal in this case is to eliminate the cylinder. If the patient is very concerned about distance vision, I would target distance. Because it is his nondominant eye, however, I would consider giving him some mild monovision so that he can recapture the near vision he is also missing.

GEORGE TATE, JR, MD

The patient appears to have developed a slight hyperopic shift and induced astigmatism at about the same time that the epithelial ingrowth occurred. I am persuaded that the ingrowth is the most likely etiology of the astigmatism, because distortion and widening of the rings on the keratoscopy view of the topography is present; it is evident in the topographic view as well as the anterior float, posterior float, and thickness views on the Orbscan (Bausch & Lomb, Rochester, NY) printout (Figure 2). Moreover, if one looks at the topographic view, the steeper island is in the approximate position to correspond to a hyperopic cylinder that is slightly above the horizontal axis. In addition, I have never felt that I could tell if epithelial ingrowth were dormant and stable as opposed to slowly progressive. Neither have I ever been able to know which ones would become reactivated, especially after surface ablation.

For these reasons, I would lift the flap in the area of the epithelial ingrowth, carefully remove the epithelium, replace the flap, and suture the edge. I am especially likely to suture the flap after removing epithelial ingrowth if there is any sign of erosion of the flap's edge, which (in my experience) increases the possibility of recurrence.

Subsequently, the patient's refractive problem may resolve. If not, I would consider an enhancement several months later, possibly as a surface procedure with adjunctive mitomycin C once the flap was stable. Lifting the flap and resuturing the edge might also be acceptable.

STEVEN J. DELL, MD

The topography in this case suggests that the astigmatism in the patient's right eye is due to the epithelial ingrowth. Considering the stable nature of the ingrowth, one possible alternative would involve customized surface ablation supplemented with the intraoperative application of mitomycin C. Although this procedure would bypass the underlying cause of the patient's astigmatism, I believe it could achieve a satisfactory result, and it would be my first choice for treatment.

This case is difficult. The surgeon could also consider simply removing the epithelial ingrowth. In hyperopic LASIK patients, this option is associated with new ingrowth and a possible devolvement into a troublesome and vicious cycle. I have treated similar patients with a partial lifting of only the involved segment of the flap and an application of Tisseel glue (Baxter Healthcare Corporation, Glendale, CA). I would advise the patient that his pursuit of a perfect result carries significant risk and jeopardizes a relatively positive current situation.

I would probably avoid a lens-based surgical solution for the patient at this point. Given the extremely low refractive error in his contralateral eye (and the eye in question, for that matter), it seems likely that this patient would be dissatisfied with any result other than emmetropia. In a post-LASIK patient, such degrees of precision in IOL power calculation are often impossible. If the ametropia were large, I

would certainly consider a lens-based solution and would adjust the IOL power according to the regression formula described by Samuel Masket, MD[1]: IOL power adjustment = LSE X (-0.326) + 0.101. *LSE* is the total prior laser treatment spherical equivalent, adjusted for vertex distance. For patients who have undergone hyperopic LASIK, the LSE is a positive number, whereas it is negative after myopic LASIK. ■

Section editors Karl G. Stonecipher, MD, and Parag A. Majmudar, MD, are cornea and refractive surgery specialists. Dr. Stonecipher is Director of Refractive Surgery at TLC in Greensboro, North Carolina. Dr. Majmudar is Associate Professor, Cornea Service, Rush University Medical Center, Chicago Cornea Consultants, Ltd. They may be reached at (336) 288-8523; stonenc@aol.com.

Stephen F. Brint, MD, is Associate Clinical Professor of Ophthalmology at Tulane University School of Medicine in New Orleans. He acknowledged no financial interest in the products or companies mentioned herein. Dr. Brint may be reached at (504) 888-2020; brintmd@aol.com.

Steven J. Dell, MD, is Director of Refractive and Corneal Surgery at Texan Eye Care in Austin. He acknowledged no financial interest in the products or companies mentioned herein. Dr. Dell may be reached at (512) 327-7000; sdell@austin.rr.com.

Ronald R. Krueger, MD, is Medical Director of the Department of Refractive Surgery at the Cole Eye Institute, Cleveland Clinic Foundation, Cleveland. He acknowledged no financial interest in the products or companies mentioned herein. Dr. Krueger may be reached at (216) 444-8158; krueger@ccf.org.

George Tate, Jr, MD, is Regional Medical Director of TLC Laser Vision Centers in Raleigh and Charlotte, North Carolina. He acknowledged no financial interest in the products or companies mentioned herein. Dr. Tate may be reached at (704) 344-0800 or (843) 693-5320; gwtatejr@yahoo.com.

1. Masket S. Simple regression formula for intraocular lens power adjustment in eyes requiring cataract surgery after excimer laser photoablation. *J Cataract Refract Surg.* 2006;32:430-434.