

Microincisional Lenses

Thin IOLs and bimanual microincisional cataract surgery are paving the way for smaller injectable IOLs.

BY MATTEO PIOVELLA, MD; FABRIZIO I. CAMESASCA, MD; AND BARBARA KUSA, MD

In the past year, cataract surgeons may have often wondered whether the frenzy about bimanual microincisional cataract surgery is warranted. The main purpose for microincisional cataract surgery is to prepare the way for injectable IOLs, with implantation through progressively smaller incisions. Several types of these new IOLs are now available, and studies on many others are underway. The time of rigid and standard foldable IOLs could be coming to an end. One-year follow-up of thin IOL implantation is providing us with interesting and positive results.

WHY A THIN IOL?

The Thinoptx lens (Thinoptx, Abingdon, VA) is a hemiacrylic (18% water), one-piece, plate-haptic, rollable IOL. This thermoplastic, 11.2-mm-wide lens has a thickness of 350 to 400 μm , depending on the power of the IOL. Thus, its thickness is one-fifth that of a standard IOL. The Thinoptx lens can easily be inserted through an incision of approximately 2 mm. Multiple 50- μm high steps and the combination of front and back IOL surface powers make the Thinoptx a refractive lens (Figure 1). Folding and insertion are now facilitated by improved injectors that prevent lens damage. Slightly warmed in BSS, the Thinoptx IOL can be easily placed in the injector. The shape of the folded IOL is uniformly cylindrical. Due to the thermoplastic properties of its material, this IOL does not expand abruptly as it

exits the injector, and it requires 20 seconds for complete unfolding.

The haptics of the IOL are designed to roll and absorb forces, thus providing optimal centration (Figure 2). Because in-the-bag rotation of the IOL may damage the capsule, we recommend first positioning the IOL on the desired axis while it is in the anterior chamber. One can then insert it into the bag by gently folding the IOL's haptics. The plate haptics feature special, teardrop-shaped fenestration holes that also allow the surgeon to easily determine which side of the IOL should face anteriorly.

CLINICAL RESULTS

Presently, we are following a group of 40 eyes of 35 patients who received the Thinoptx IOL. The mean, final incisional width, calculated with a caliper measurement of the internal tunnel after IOL insertion, was 2.37 ± 0.36 mm. One-year results demonstrated a mean visual acuity of 20/23 with a mean spherical equivalent correction of -0.19 ± 0.68 D. Endothelial cell counts decreased by an average of 9.2% at




Figure 1. The high-magnification image shows the multiple 50- μm high steps that, together with the combination of front and back IOL surface powers, make the Thinoptx a refractive lens (A). After insertion, the Thinoptx lens is shown with the retinal red reflex in a fully dilated eye (B).

1 year. Interestingly, the amount of coma and spherical and higher-order aberrations, measured at 1 year with the WASCA Analyzer (Carl Zeiss Meditec AG, Jena, Germany), were not significantly greater when compared with normal population values.

We are presently evaluating other factors, such as the frequency of posterior capsular opacification. The Thinoptx lens, due to its peculiar shape, lacks a square edge, and thus the frequency of posterior capsular opacification appears to be higher than with square-edge IOLs such as the Sensar (Advanced Medical Optics, Inc., Santa Ana, CA). Nonetheless, the posterior capsular opacification rate appears to be much lower when compared with rigid PMMA IOLs.

SURGICAL TECHNIQUE

For our study, we used topical anesthesia and the following instrumentation: 1.3-mm-wide sapphire knives for the microincisional tunnel and sideport, coaxial forceps for the capsulorhexis, and 0.9-mm phaco microincisional tips. We also used a separate irrigation source through a sideport incision. The two most critical steps of microincisional cataract surgery are (1) creating the incision and (2) making the capsulorhexis. Tunnel creation must respect a delicate balance: a tunnel too short may easily lead to iris chafing or prolapse, and the insertion of surgical instruments through a small tunnel may be difficult when its three planes are very steep.

Due to limited tunnel width, the capsulorhexis must be performed with forceps that do not open in the usual way (without the proper instrument, grasping and guiding the capsulorhexis is difficult). A new generation of 23-gauge coaxial rhexis forceps that work like vitrectomy instruments is presently available, and they make this step similar to the usual 3.4-mm tunnel situation. Microincisional phaco tips are now available with a 0.9-mm outside diameter, and they may also be carbon-coated to reduce friction and heat generation during surgery. A 0.9-mm microincisional phaco tip without an irrigation sleeve requires a 1.3-mm incision. Irrigation is provided through 1.1-mm sideport, and newly designed instruments presently provide both the irrigation and the chopper functions. A chopper with a front opening for irrigation will ensure better irrigation and chamber stability compared with a side-irrigating chopper. Because the small incision constrains movement of the phaco tip, most surgeons performing bimanual microincisional surgery presently

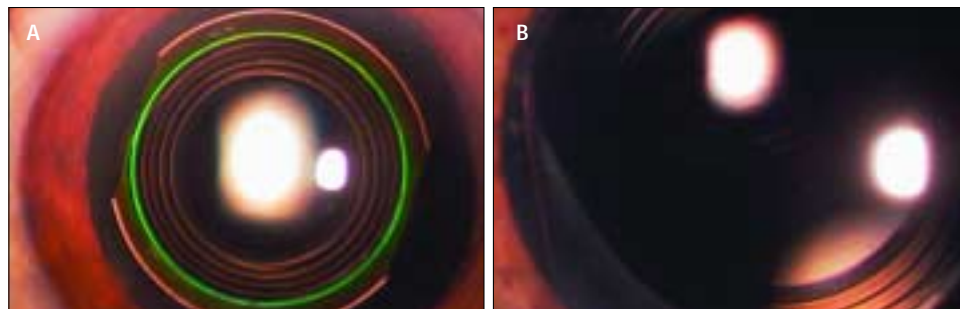


Figure 2. The Thinoptx IOL demonstrates good centration and stability, even with a fully dilated pupil (A). The inserted lens is viewed with high magnification (B).

adopt a phaco chop technique. It is possible, however, that a completely new surgical technique will be developed to maximize the advantages offered by bimanual microincisional surgery. Finally, the I/A step is performed with bimanual, Buratto-style cannulas.

We believe that caution must be applied when choosing instrumentation for bimanual microincisional surgery. Several generations of instruments have evolved over the course of 1 year. It is therefore desirable to select the newest instruments that incorporate the latest technical improvements.

CONCLUSION

Bimanual microincisional cataract surgery adds a certain degree of surgical complexity and therefore increases surgical and phaco times. A learning curve definitely exists to safely mastering this new technique. We believe ultrathin, injectable IOLs will end these efforts on the part of transitioning surgeons and instrument companies.

In our hands, the Thinoptx IOL makes bimanual microincisional surgery a worthwhile endeavor. ■

Matteo Piovella, MD, is Chairman at the Centro Microchirurgia Ambulatoriale in Monza, Italy. He states that he holds no financial interest in the products or companies mentioned herein. Dr. Piovella may be reached at +39039389498; piovella@piovella.com.



Fabrizio Camesasca, MD, is Vice Chairman, Department of Ophthalmology, Istituto Clinico Humanitas in Milan, Italy. He states that he holds no financial interest in the products or companies mentioned herein. Dr. Camesasca may be reached at +390282242311; fabrizio.camesasca@tiscali.it.



Barbara Kusa, MD, is Consultant at the Centro Microchirurgia Ambulatoriale in Monza, Italy. She states that she holds no financial interest in the products or companies mentioned herein. Dr. Kusa may be reached at +39039389498; piovella@piovella.com.

