

Decentered LASIK Ablation

BY MATTHIAS J. MAUS, MD; BRIAN S. BOXER WACHLER, MD; EDWARD E. MANCHE, MD;
ROBERT K. MALONEY, MD; AND GILLES LAFOND, MD

CASE PRESENTATION

A 39-year-old male underwent bilateral LASIK surgery in July 2000 and has been referred to your office by a fellow LASIK surgeon. Surgery in his left eye was uneventful. A shorter-than-expected translation of the microkeratome occurred during the treatment of his right eye, but the surgeon decided there was room for laser ablation with protection of the flap's hinge and proceeded. Figure 1 shows corneal topography as measured by the Magellan Mapper Corneal Topographer (Nidek Co., Ltd., Gamagori, Japan; distributed in the US by Nidek Technologies America, Greensboro, NC). Reproducible wavefront measurements could not be obtained with currently available technology. Figure 2 shows an Orbscan image (Bausch & Lomb, Rochester, NY) for the patient's right eye. The case represents a classic, decentered ablation secondary to the creation of a short flap intraoperatively.

With a correction of -1.00 +1.00 X 180, the patient achieves a visual acuity of 20/30 with difficulty in his right eye and describes ghosting as well as secondary images. He has a UCVA of 20/60 OD, and his pachymetry reading is 505 μm . Residual stromal bed readings were not evaluated at the time of surgery. The patient has a crisp UCVA of 20/20 OS. Because his right eye is dominant, he is limited in his performance of daily activities. Contact lens fitting with a variety of types and styles of lenses has been unsuccessful, despite efforts by multiple specialists who work specifically with postrefractive surgery patients. The patient's visual acuity is limiting his career opportunities, and he asks you about surgical options in the wake of failed medical management.

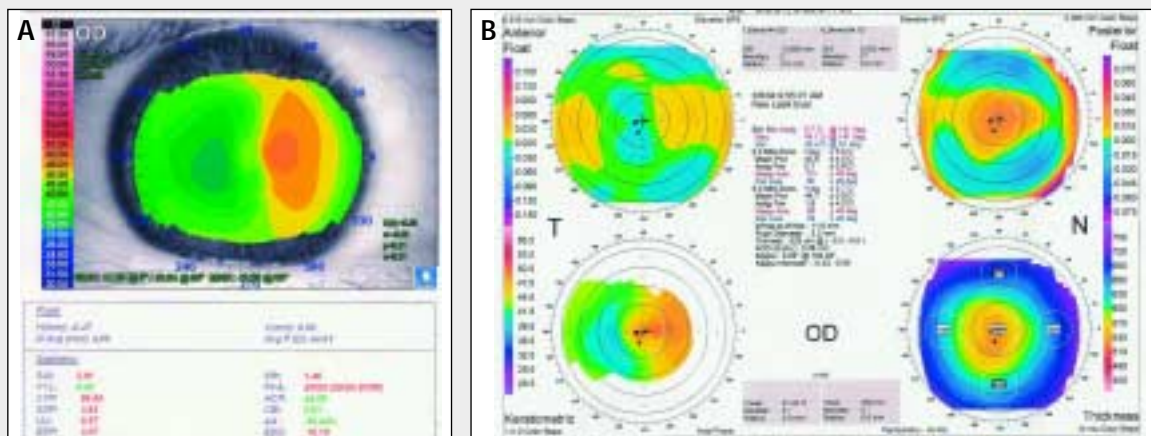


Figure 1. Topographic measurements by the Magellan Mapper Corneal Topographer showed classic decentration of a laser ablation profile (A). Imaging with the Orbscan topographer confirmed decentration, and pachymetry showed the presence of sufficient corneal tissue (B).

MATTHIAS J. MAUS, MD

LASIK decentrations affect the visual pathway, primarily by inducing tilt and coma on the cornea. Coma is the main factor causing the ghosting and secondary images seen by this patient's right eye. The role of tilting in this case may be negligible, because the topographic pattern is typical for coma alone.

I think that topography-guided LASIK holds the best potential for improving this patient's visual function. For this treatment option, placido ring-based measurements of the anterior corneal surface are transferred into height data referring to a plane, which references the corneal apex. Due to the great sensitivity of decentrations in the z axis, I would perform a topography-guided treatment

with the Topolyzer system (Oculus Optikgeräte GmbH, Wetzlar, Germany). Its built-in keratometer reduces the error in height calculations to between 3 and 4 μm versus 30 to 40 μm with standard systems (unpublished data, WaveLight Laser Technologie AG, Erlangen, Germany). The system also compensates for a slightly decentered measurement in all three axes.

After taking at least four (eight would be preferable) reproducible measurements, the Topolyzer system uses the mean topography to calculate the height data and translates them into Zernike factors. After optical zone selection, the system calculates the ablation pattern and prescribes a desirable postoperative asphericity (Q value) within the physiologically normal range.

Whether to address tilt remains a question, mainly because most patients easily tolerate a certain amount of tilt and because its treatment consumes additional tissue. I usually treat tilt if (1) sufficient tissue is present and (2) the offset between the corneal apex and the center of the pupil is greater than 1 mm. I also must choose between the manifest refraction and the refraction suggested by the system. Presenting both refractions to the patient via the phoropter can make the decision easier.

Patients must understand that they will likely require a second retreatment, because the predictability of refraction is poor during the first retreatment procedure. The second treatment may be either wavefront-guided or wavefront-optimized. Knowing this patient's preoperative refractions and K readings would be of benefit.

BRIAN S. BOXER WACHLER, MD

The dramatic temporal flattening and nasal steepening on topography account for a change of greater than 10.00 D across the patient's pupil. This finding indicates a high degree of induced horizontal coma, which explains his poor BCVA and has, I would predict, an even greater impact on his contrast sensitivity. A surface wavefront retreatment (either PRK or LASEK) with topical mitomycin C (MMC) to prevent haze would significantly reduce this patient's symptoms. It is not advisable to lift the pre-existing short flap, which is a partial cause of his aberrations. Recutting a flap with a microkeratome or the Intralase FS laser (Intralase Corp., Irvine, CA) is an option, but it represents a higher risk than surface ablation with MMC.

I recently treated a similar case of myopic decentered ablation with the LADARVision CustomCornea Wavefront System (Alcon Laboratories, Inc., Fort Worth, TX). The patient had a normal flap and high, induced, horizontal coma of 1.56 μm after conventional LASIK. Figure 2 demonstrates the striking recenteration of the postwavefront topography as well as the re-establishment of a prolate profile. I have also found this platform to be hearty in its ability to reliably

capture wavefront images of abnormally shaped corneas after LASIK or PRK.

EDWARD E. MANCHE, MD

This case is a tough one to manage. Unfortunately, the patient is unable to wear a rigid gas permeable contact lens, which would be my first choice in management. Additionally, his eye cannot be imaged with currently commercially available aberrometers. I would therefore proceed by measuring the patient's topography using the VisionPro software for the Humphrey ATLAS Corneal Topography System (Carl Zeiss Meditec Inc., Dublin, CA). Next, I would use elevation maps to plan a Visx Custom Contoured Ablation Pattern (Custom-CAP; Visx, Inc., Santa Clara, CA). I have had great success using this topography-driven technology for similar cases.

I would perform surface ablation augmented with MMC to prevent corneal scarring. One reason I would not recommend creating an additional LASIK flap is that it could produce flap slivers if the two primary keratotomy flaps crossed inadvertently. Second, in my experience, a patient such as this one will require at least one additional procedure after the Visx Custom-CAP treatment. Lifting the flap in an eye with multiple flaps greatly increases the risk of flap separation and misalignment, both of which can lead to problems such as irregular astigmatism in an eye with serious pre-existing pathology.

I have found treatments with Visx Custom-CAP to be highly effective at regularizing the corneal surface. Following the Visx Custom-CAP procedure, I would allow this patient's eye to heal for 6 months and would then reimaging it with an aberrometer in order to prepare for a wavefront-

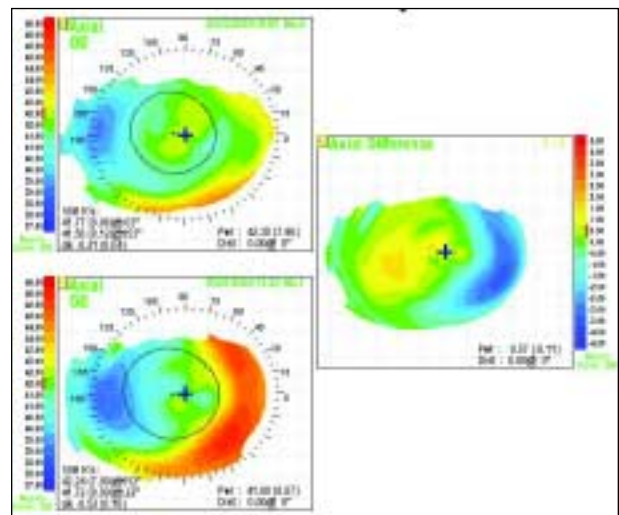


Figure 2. The prewavefront (lower left) and postwavefront (upper left) topographies as well as the difference map (right) of Dr. Boxer Wachler's patient are shown.

guided retreatment. I have been able to successfully image nearly all of the eyes that I have treated using Visx Custom-CAP with a variety of commercially available aberrometers postoperatively. Finally, I would perform a wavefront-guided retreatment using surface ablation to address the residual refractive error and remaining aberrations.

ROBERT K. MALONEY, MD

This patient clearly has a nasally hinged flap. Blockage of the ablation in the area of the hinge produced the apparent decentration. It is not unusual for the current generation of wavefront instruments to be unable to properly analyze eyes with aberrations of this significance.

My preference would be to recut the flap with a plate of the same depth used to produce a normal flap. I would then complete the ablation by means of a Visx Custom-CAP treatment in order to produce a symmetrical ablation. This treatment would likely reduce the patient's amount of astigmatism and improve his BSCVA while regularizing his topography. A wavefront-guided therapeutic retreatment would then probably be necessary as a way to fine-tune the patient's refraction and address residual aberrations.

GILLES LAFOND, MD

The postoperative topography for this case demonstrates both a decentration and a truncated ablation zone. Due to the incomplete LASIK flap, the nasal half of the treatment has not been delivered. The flatter, temporal ablation zone is 39.00 D, and the steeper, nasal, undertreated zone is 49.50 D. This irregular corneal surface has cost the patient two lines of BCVA, induced astigmatism, and produced ghosting and secondary images. This complicated case illustrates well the importance of a basic rule in refractive surgery: never deliver the excimer laser treatment if the flap is not adequate. An incomplete small or irregular LASIK flap should be replaced without laser treatment and allowed to heal. Several months later, the surgeon may cut a new flap and proceed with the laser ablation.

When re-treating an undercorrection with an adequate flap, I generally prefer to relift the original flap. In the case of an inadequate initial flap, a new flap must be cut to expose a larger-diameter corneal bed. To allow the original flap sufficient time to heal, I wait 4 months before performing the second cut.

The difficulty in re-treating this case is achieving a regular corneal surface. Possibly, in the future, customized ablation will be the solution for such retreatments. At present, the number of reported retreatment cases with existing technology is limited, and results are variable. Although wavefront-guided treatments can correct higher-order aberrations successfully, they have not been effective in the retreatment of significantly distorted corneas. For such

marked irregularities located on the front surface of the cornea, customized ablation based on topographical measurements seems more appropriate. Surgeons have used the MEL 70 (Carl Zeiss Meditec Inc.), with its TOSCA program, for several years to perform customized ablations based on topographic measurements. This system has reportedly achieved good results in some retreatments of very irregular corneas.¹⁻³ I have no personal experience with this laser, however, and it is not yet approved by the FDA.

A second option involves delivering additional myopic correction. By simultaneously blocking the temporal half of the treatment, additional ablation will occur only on the untreated nasal half of the cornea. It is difficult, however, to place the protection at the optimal location. If protection is too nasal, an untreated zone will persist in the center of the cornea. Protection located too temporally will allow additional treatment in an area that has already been fully corrected and could result in persistent corneal irregularity with overcorrection.

A third option is to combine a myopic and hyperopic ablation. The hyperopic ablation is decentered in the same direction as the initial myopic ablation, and a myopic ablation of a nearly equivalent dioptric value is decentered in the opposite direction. Because these ablations overlap in the corneal center, their respective refractive effects are neutralized, and the eye's refractive status should not change significantly. I have used this empirical technique in several cases of decentered or irregular ablations and have been successful in the majority of cases.^{4,5}

For this patient, I suggest a +1.50-D ablation with a 1.5-mm decentration at 190° and a -2.00-D ablation with a 1.5-mm decentration at 10°. The myopic ablation exceeds the hyperopic ablation by 0.50 D because the patient is undercorrected by -0.50 D (spherical equivalent). I do not advise using a toric ablation in this case; the residual cylinder resulting from the initial surgery is probably the consequence of the ridge present between the treated and untreated zones of the cornea. Enlarging and recentering the ablation zone with decentered spherical ablation should reduce the amount of cylinder. After the initial retreatment, some residual ametropia or decentration may persist. If so, the surgeon can relift the LASIK flap during the first postoperative week in order to perform an enhancement.

Before proceeding with any surgical option, this patient should be informed that optimal vision rehabilitation sometimes requires more than one retreatment session. ■

Section editor Karl G. Stonecipher, MD, is Director of Refractive Surgery at Southeastern Eye Center in Greensboro, North Carolina. Dr. Stonecipher may be reached at (800) 632-0428; stonenc@aol.com.

Brian S. Boxer Wachler, MD, is Director of the Boxer Wachler Vision Institute in Beverly Hills, California. He is a consultant for Alcon Laboratories, Inc. Dr. Boxer Wachler may be reached at (310) 860-1900; bbw@boxerwachler.com.



Gilles Lafond, MD, is Clinical Professor for the ophthalmology program at Laval University in Quebec City, Canada, and he is Director of the Institut de Micro-Chirurgie Oculaire et de Laser de Québec in Canada. He does not hold a financial interest in the products or companies mentioned herein. Dr. Lafond may be reached at (418) 658-6345; gilles.lafond@videotron.ca.



Robert K. Maloney, MD, is Director of the Maloney Vision Institute in Los Angeles, California. He is a consultant for Visx, Inc. Dr. Maloney may be reached at (310) 208-3937; drmaloney@maloneyvision.com.



Edward E. Manche, MD, is Director of Cornea and Refractive Surgery as well as Associate Professor for the Department of Ophthalmology at Stanford University School of Medicine, Stanford, California. He does not hold a financial interest in the products or companies mentioned herein. Dr. Manche may be reached at (650) 725-5743; edward.manche@stanford.edu.



Matthias J. Maus, MD, is Director of AUGENZENTRUM Maus+Heiser in Cologne, Germany. He is a paid consultant to WaveLight Laser Technologie AG. Dr. Maus may be reached at +49 221 860 1613; maus@augenzentrum.de.



1. Wygledowska-Promienska D, Zawajska I, Gierek-Ciaciura S, Sarzynski A. Correction of irregular astigmatism using excimer laser MEL 70 G-Scan with the TOSCA program. *Klin Oczna*. 2000;102:443-447.
2. Nagy ZZ. Laser in situ keratomileusis combined with topography-supported customized ablation after repeated penetrating keratoplasty. *J Cataract Refract Surg*. 2003;29:792-794.
3. Lee DH, Seo SJ, Shin SC. Topography-guided excimer laser ablation of irregular cornea resulting from penetrating injury. *J Cataract Refract Surg*. 2002;28:186-188.
4. Lafond G, Bonnet S, Solomon L. Treatment of previous decentered excimer laser ablation with combined myopic and hyperopic ablations. *J Refract Surg*. 2004;20:139-148.
5. Lafond G. Surgeon-guided retreatment of irregular astigmatism and aberrations. In: Krueger RR, Applegate RA, MacRae SM, eds. *Wavefront Customized Visual Correction*. Thorofare, NJ: Slack, Inc.; 2004: 339-352.

SHARE THE CHALLENGE

Do you have a complicated case that you would like to share for discussion? The case presentation should be formatted similarly to that of this article and should be accompanied by one or two appropriate figures. E-mail your case and artwork to *Cataract & Refractive Surgery Today* at cases@bmctoday.com.