

# Innovation for Advancement

Always seek opportunities to improve cataract surgery.

BY JAMES P. GILLS, MD

*From every profession rises a superstar. Recent examples include Tiger Woods in golf, Oprah Winfrey in daytime talk shows, and Yo-Yo Ma in cello music. For ophthalmology, the late Charles Kelman, MD, has been succeeded by James Gills, MD.*

*Jim's innovations in the field have improved the safety of cataract surgery and increased patients' comfort and the speed of their visual recovery. Modern cataract surgery owes much of its amazing success to the likes of Charlie and Jim.*

—Herve M. Byron, MD, Section Editor

**T**he great innovators of ophthalmology have shaped many of our careers. Several mentors pushed me to be a better surgeon and to think outside the box. Of all the formidable influences on my career, however, none had the impact of a 70-year-old woman who visited my office from Florida's east coast in 1971. Smartly dressed, she carried herself in a manner that conveyed that she knew what she wanted. She was intelligent and articulate, and she sat in my examination chair with a twinkle in her eye.

As I looked through the slit lamp, I was surprised to see a square pupil and an IOL. I finished the examination and sat back. She wasted no time and addressed me somewhat differently than I would have expected. "Son, the look on your face tells me that you don't approve of my implant," she said. "I've been to six other doctors before you, and none of them approved of it, either. In fact, I don't think any of them had even seen one before." I was not anxious to admit to her that I had not seen one, either.

She proceeded to tell me that I seemed like a "nice young boy" and that, if I wanted to be a really great surgeon, I should learn about lens implants. I could easily have been put off by her commanding attitude, but I took up the challenge.

## MY EARLY EXPERIENCE WITH IOLS

I had already converted to extracapsular cataract extraction (ECCE),<sup>1</sup> thanks in part to Henry Hirschman, MD. The timing for IOLs was therefore perfect. Surgeons who made the transition to ECCE were criticized by those who were still performing intracapsular cataract extraction. I knew I

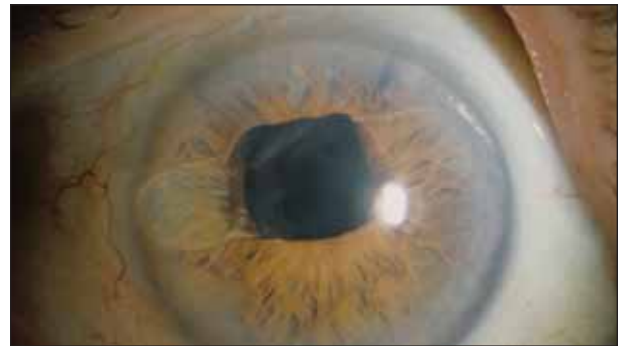


Figure 1. Dr. Gills began implanting the Copeland lens (seen here in 1983) when phacoemulsification and IOL implantation were still controversial.

would also be condemned for using IOLs, but my instincts told me that innovators such as Harold Ridley; Norman Jaffe, MD; Herve Byron, MD; Miles Galin, MD; and Cornelius Binkhorst, MD, were all on the right track.

I read Dr. Jaffe's work,<sup>2</sup> watched his films, and soon started using the Copeland lens (Figure 1). I will never forget the uproar in the ophthalmic community at that time. Disapproving surgeons called the lenses *time bombs* and publicly ridiculed anyone implanting them. Rather than stifle innovation, the opposition only intensified the excitement surrounding the new development. It was an incredible time when a sharp line divided the progressive thinkers from the traditionalists. Soon, I was the first ophthalmologist to dedicate my practice solely to the treatment of cataracts with IOLs. The ophthalmic establishment considered me a charlatan.

## INNOVATIONS

### Bupivacaine

The time was right for questioning the status quo, and I did. Later in 1968, I met with Irving Leopold, MD, who suggested that I bring bupivacaine<sup>3</sup> to the US, because we needed a longer-acting anesthesia. I took his advice, and, thanks to a mention at the AAO Annual Meeting by Charles Kelman, MD, the drug was soon widely used.

### The Gills-Welch Technique

In the years that followed, I began teaching ECCE with Robert Welch, MD. We taught the Gills-Welch technique to 5,000 surgeons in just 10 years. I had studied Dr. Binkhorst's extracapsular technique in which he used loupes and decided to incorporate a microscope, which I had learned to use from my experience in neurosurgery. After delivering the lens with either hydraulic delivery or a lens loupe, the surgeon cleaned up the remaining cortical material with a two-lumen needle. An anterior chamber maintainer was frequently used, according to the technique of Michael Blumenthal, MD. Drawing on the ideas of many surgeons, I performed 50,000 planned ECCEs. Using that approach, I performed 5,000 consecutive cases without a single incidence of vitreous loss, and the technique is still used today by ophthalmologists in third world countries with great success.

### IOL Power Calculations

In the late 1970s, I cowrote the first empirical lens power formula with Thomas Loyd, PA. It was the first formula to take into consideration long, average, and short eyes. It had a tremendous effect on the accuracy of our outcomes and drew the attention of some creative, brilliant minds that built on it.

### Intraocular Antibiotics

I was interested in improving the safety of cataract surgery. I had been following the work of Gholam Peyman, MD,<sup>4,6</sup> and Robert Machemer, MD,<sup>7</sup> who were injecting vancomycin into the vitreous. I sought their counsel on using intraocular antibiotics for cataract surgery. I started with a conservative dosage that was one tenth of the therapeutic dose. I mixed the antibiotics into the irrigating solution. Dr. Jaffe and Robert Drews, MD, both told me that the integrity of the antibiotics in the irrigating solution was relatively short, so I decided to filter the irrigating solutions for additional protection.<sup>8</sup> Little did I know what powerful safety the combination of those measures would provide.

Several years after I began filtering my irrigating solutions, a batch of balanced salt solution that was contaminated with *Paecilomyces lilacinus* caused an epidemic of endophthalmitis.<sup>9</sup> Some of my colleagues lost as many as 20 eyes. One afternoon, I received a phone call from a well-intentioned professor who informed me that dozens of my

patients would soon be blind. My blood ran cold. Incredibly, I did not have a single infection. I attribute that narrow escape to my filtering the irrigating solutions.

### Astigmatic Correction

As phacoemulsification became the new standard of care, it spurred the development of foldable IOLs. Incisions became smaller and, finally, sutureless. I had always been interested in minimizing astigmatism, and I saw an opportunity to give my patients an excellent refractive outcome. One day in the early 1990s, J. James Rowsey, MD, accompanied four surgeons and me on a visit to Stephen Hollis, MD. He was an innovative surgeon who was performing peripheral relaxing incisions. I adopted his technique and became obsessed with correcting astigmatism. Since then, I have performed 60,000 relaxing incisions and implanted 14,000 toric lenses.

### Intraocular Medications

The next big advance in cataract surgery was topical anesthesia,<sup>10</sup> and I was among the first surgeons to use it. Although my patients did well overall, most complained of pressure and discomfort during surgery. My interest in intraocular anesthesia had been piqued sometime earlier when Robert Hustead, MD; Donald Sanders, MD; and I were working on our textbook *Ophthalmic Anesthesia*.<sup>11</sup> We discovered cases of anesthesia inadvertently injected into the anterior chamber for which, miraculously, there were no ill effects on the patient.

I conducted some dose-ranging research on eyes with limited visual potential without a single adverse effect and also performed a prospective study under the guidance of Dr. Sanders. Shortly thereafter, I made intraocular lidocaine part of my standard protocol for anesthesia.<sup>12</sup> Its use allowed the majority of my patients to safely enjoy the benefits of topical anesthesia.

Using intraocular medication has been a theme of my career. As Willie Sutton said, "You go where the money is." My concept has been to place medication inside the eye. When I read about retina surgeons who were injecting as much as 25 mg of Kenalog (Bristol-Myers Squibb Company, New York, NY) into the posterior chamber without adverse effects, I questioned whether the drug could reduce the number of drops cataract surgery patients needed postoperatively.<sup>13-16</sup> Using just a fraction of the therapeutic dose for retina patients, I began injecting Kenalog into the anterior chamber.<sup>17</sup> I quickly determined that my patients did not need to follow the tedious schedule of postoperative drops that I had been prescribing. I have since found that combining topical steroids and NSAIDs with a sub-Tenon's injection of Kenalog is the most effective means of controlling postoperative inflammation.

### Povidone-iodine

Today, I continue to focus on improving cataract surgery's safety. Most recently, I developed a technique of neutralizing the pH of my povidone-iodine solution. In so doing, I have eliminated the toxic effects of the solution on the cornea and conjunctiva as well as patients' subsequent complaints of dry eyes postoperatively.

### CONCLUSION

I have had the privilege of experiencing a golden era in ophthalmology and participating in incredible advances in technology and surgical technique. Those of us pushing for change in the early 1970s were not worried about making history; we just wanted to do the best we could for our patients. Tomorrow holds just as much promise and potential as ever. It would be easy to focus on what is more difficult about being an ophthalmologist today compared with 30 years ago. Instead, I choose to look ahead for the next opportunity to provide my patients with better surgical outcomes. ■

*James P. Gills, MD, is Founder and Director of St. Luke's Cataract & Laser Institute in Tarpon Springs, Florida. He acknowledged no financial*



*interest in the product or company mentioned herein. Dr. Gills may be reached at (727) 943-3111 ext. 2431; jgills@stlukeseye.com.*

1. Gills JP, Loyd TL. Extracapsular cataract extraction with intraocular lens insertion. *J Am Intraocul Implant Soc.* 1979;5:9-12.
2. Jaffe NS. Suggested guidelines for intraocular lens implant surgery. *Arch Ophthalmol.* 1976;94:214-216.
3. Gills JP, Rudisill JE. Bupivacaine in cataract surgery. *Ophthalmic Surg.* 1974;5:67-70.
4. Peyman GA, Herbst R. Bacterial endophthalmitis. Treatment with intraocular injection of gentamicin and dexamethasone. *Arch Ophthalmol.* 1974;91:416-418.
5. Peyman GA, May DR, Ericson ES, Apple D. Intraocular injection of gentamicin. Toxic effects of clearance. *Arch Ophthalmol.* 1974;92:42-47.
6. Peyman GA, Nelsen P, Bennett TO. Intravitreal injection of kanamycin in experimentally induced endophthalmitis. *Can J Ophthalmol.* 1974;9:322-327.
7. Machemer R. Subtotal vitrectomy through the pars plana. *Trans Am Acad Ophthalmol Otolaryngol.* 1973;77:OP198-201.
8. Gills JP. Antibiotics in irrigating solutions. *J Cataract Refract Surg.* 1987;13:344.
9. Miller GR, Rebell G, Magoon RC, et al. Intravitreal antimycotic therapy and the cure of mycotic endophthalmitis caused by a *Paecilomyces lilacinus* contaminated pseudophakos. *Ophthalmic Surg.* 1978;9:54-63.
10. Kershner RM. Topical anesthesia for small incision self-sealing cataract surgery. A prospective evaluation of the first 100 patients. *J Cataract Refract Surg.* 1993;19:290-292.
11. Gills JP, Husted RF, Sanders DR, ed. *Ophthalmic Anesthesia.* Slack, Inc.: Thorofare, NJ; 1993.
12. Gills JP, Cherchio M, Raanan MG. Unpreserved lidocaine to control discomfort during cataract surgery using topical anesthesia. *J Cataract Refract Surg.* 1997;23:545-550.
13. Jonas JB, Degenring R, Kreissig I, Akkoyun I. Safety of intravitreal high-dose reinjections of triamcinolone acetonide. *Am J Ophthalmol.* 2004;138:1054-1055.
14. Jonas JB. Concentration of intravitreally injected triamcinolone acetonide in aqueous humour. *Br J Ophthalmol.* 2002;86:1066.
15. Beer PM, Bakri SJ, Singh RJ, et al. Intraocular concentration and pharmacokinetics of triamcinolone acetonide after a single intravitreal injection. *Ophthalmology.* 2003;110:681-686.
16. McCuen BW 2nd, Bessler M, Tano Y, et al. The lack of toxicity of intravitreally administered triamcinolone acetonide. *Am J Ophthalmol.* 1981;91:785-788.
17. Gills JP, Gills P. Effect of intracameral triamcinolone to control inflammation following cataract surgery. *J Cataract Refract Surg.* 2005;31:1670-1671.