

The Renaissance of Keratophakia

Results from the clinical studies of the Anamed stromal implants.

BY STEPHEN G. SLADE, MD, FACS

Refractive surgery can be divided into three main categories: (1) corneal bending (eg, RK, the placement of Intacs segments [Addition Technology, Inc., Des Plaines, IL], and conductive keratoplasty); (2) surgical techniques that remove tissue (eg, PRK and LASIK); and (3) lens-based procedures. This article focuses on keratophakia and the Anamed stromal implants (PermaVision lenses; Anamed Inc., Lake Forest, CA), which are currently in phase II clinical trials. Categorizing this technology is difficult, because this lens changes the anterior curvature of the cornea.

KERATOPHAKIA THEN AND NOW

LASIK is an excellent procedure for myopes. In hyperopes, however, the procedure is less successful, because it takes far longer to perform and subtracts more tissue. The first keratophakia surgery was performed in 1949 by Professor José Barraquer, MD. Twenty years ago, my colleagues and I had a cryolathe on which we would grind a frozen disc of corneal tissue into a lens, place it under a corneal disc, and suture the disc in place on the patient's eye. The procedure was innovative but ultimately did not work well, largely due to the induction of irregular astigmatism. Because the requisite human corneal tissue was not always available, investigators such as Dr. Barraquer began to seek an appropriate synthetic tissue that could be used in the procedure.

The Anamed implant is composed of the company's proprietary, microporous, hema-based silicone hydrogel called *Nutrapore* that mimics the human stroma. The material is 78% water and is highly permeable to water, oxygen, and glucose. The lens is approximately 5.5 mm in diameter, has a refractive index of 1.376 ± 0.005 , and provides wonderful optical clarity (99% transmission).

Animal studies of this technology began 4 years ago (Anamed Inc., data on file). Investigators found that the lenses were stable in pig eyes and that the corneas remained clear. After sacrificing the animals, they discerned no stress on the keratocytes, no tissue reaction, and no hypertrophy of the epithelium.

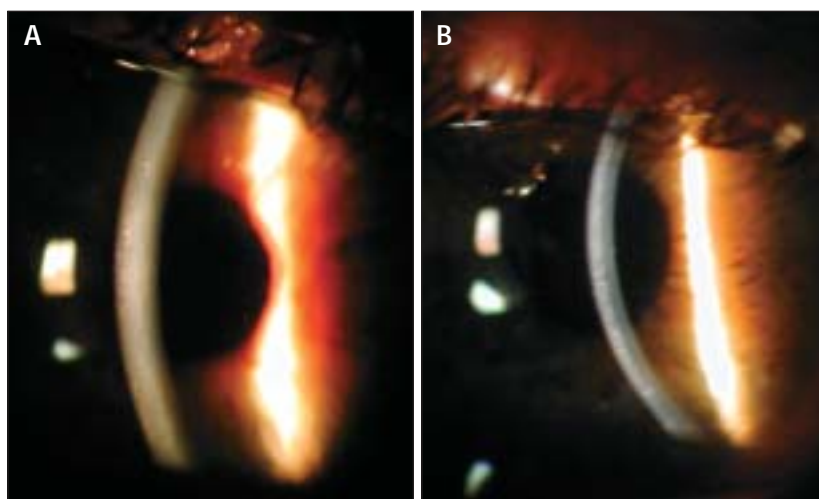


Figure 1. One day after surgery, the eye is calm, and it is difficult to see the lens. As is typical, some edema from the surgery is present. For that reason, patients should be overcorrected by approximately 0.50 to 1.00 D (A). Three months postoperatively, the eye is calm, and the lens and cornea are clear. The implant is hardly visible at the 5-o'clock position (B).

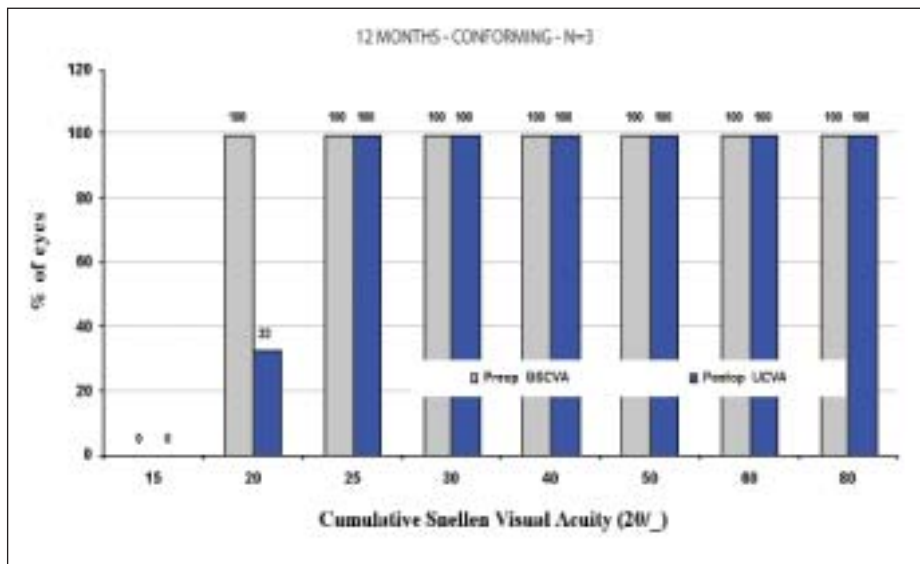


Figure 2. The plot for UCVA over time shows results that compare favorably to those with current laser technology.

THE PROCEDURE

As an investigator in the human clinical trials, I have found the surgical procedure for placing the Anamed stromal implant to be fairly simple. After flap creation, the surgeon must clean the bed meticulously so that no blood or foreign matter is present when he places the implant. The delivery device for the lens is a titanium spoon. The surgeon either nudges the implant off the spoon or inverts the spoon to press the implant onto the stromal bed. The surgeon then replaces the flap. The implant's edge is difficult to discern postoperatively (Figure 1). Figures 2 and 3 summarize the latest results with the PermaVision lenses.

COMPLICATIONS

Lens decentration occurred in approximately 20% of cases in the phase I trial (Figure 4). Fortunately, the procedure is adjustable, and recentration was successful in the majority of cases in which decentration induced astigmatism. In two cases, however, decentration recurred, and the lenses were explanted. An inversion of the lens will cause late-onset re-

gression (at 6 months and onward). Inversion is apparent on topographic maps as a steepening at the periphery of the lens. Prevention entails carefully following the insertion instructions and avoiding turning over the lens. No patient has developed diffuse lamellar keratitis or infection thus far, but these complications would be good reasons to remove the lens.

PHASE II STUDY

In the phase II US clinical trial, five sites are open, and 22 eyes have received the lens thus far. Three of

these eyes have reached 24-month follow-up. To date, we have had no instances of corneal haze and only one adverse event—the unrelated development of a cataract. Of the five eyes for which we have 6-month follow-up data, 80% have a UCVA of 20/40 or better and a manifest refraction spherical equivalent of ± 2.00 D. No eye has lost two or more lines of BSCVA or has a BSCVA worse than 20/40. I am using the INTRALASE FS laser (IntraLase Corp., Irvine, CA) in order to initiate the study of more customized flap creation for lens implantation.

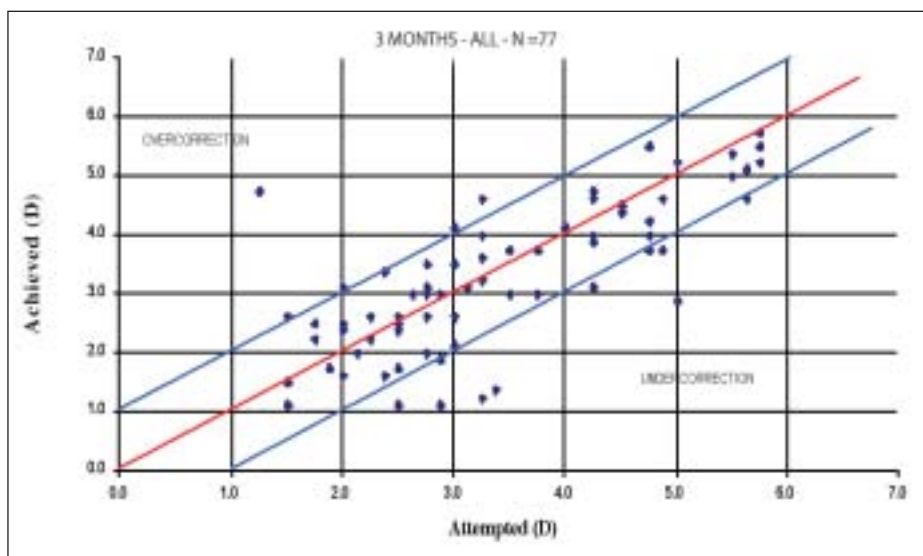


Figure 3. Predictability was very good at 3 months. There was a tendency toward undercorrection in these early, consecutive, first cases.



Figure 4. One day postoperatively, the lens has become inferiorly decentered.

CONCLUSION

Keratophakia is theoretically attractive because it is potentially reversible and adjustable. The procedure removes no tissue and can correct large amounts of

hyperopia. In the past, the procedure was limited by early keratomes that induced irregular astigmatism and by issues related to the availability of corneal tissue. Modern microkeratomes have solved the problem of induced irregular astigmatism, and my co-investigators and I hope that the PermaVision lenses will address the issue of tissue availability.

Early results with the implants are promising, as evidenced by the FDA's allowing the expansion and continuation of our study. We are also adding a presbyopic inlay to our study. This lens has the potential to solve the twin problems of centration and reversibility associated with multifocal IOLs and/or presbyopic excimer laser ablations. Centration of multifocal IOLs can be difficult, and patients may balk at the removal of the lenses. Although the laser ablation can be centered, it cannot be reversed. Presbyopic inlays could be centered and, if necessary, removed. ■

Stephen G. Slade, MD, FACS, is in private practice in Houston. He is not a consultant for and does not receive money from Anamed Inc., but he does hold a small number of options in the company. Dr. Slade may be reached at (713) 626-5544; sgs@visiontexas.com.

