

Successful Capsulorhexis Creation



As evidenced by the subsequent tips, the importance of a deep anterior chamber, maintained by the adequate use of an ophthalmic viscosurgical device (OVD), is apparent. In addition to using an appropriate volume of an OVD, another way to enhance the deep anterior chamber is to loosen the lid speculum and ensure that the drapes are not pulling on the ocular adnexae.

Additionally, as Dr. Bakewell notes later, a basic principle when tearing the capsulorhexis with a forceps is to regrasp frequently, near the tear's origin, in order to prevent the tear from rapidly spiraling outward. Finally, a forceps with a curved tip is useful for reaching over the crystalline lens when creating the tear opposite to the incision.

I hope that the pearls included in this article—each from an experienced surgeon and teacher—assist you in obtaining satisfactory outcomes with your capsulorhexis.

WILLIAM J. FISHKIND, MD, FACS, SECTION EDITOR

R. BRUCE WALLACE III, MD, FACS

After successfully completing an anterior capsulotomy, Cincinnati cataract surgeon Bobby Osher commonly remarks to his patient, "You can relax now. The most difficult part of the procedure is over." Because the anterior capsulotomy dictates how the rest of the procedure will go, any steps surgeons can take to be more predictable make sense. Following are five tips to consider.

1. Program the capsulotomy size by using a corneal diameter mark. I use an optical zone marker on the

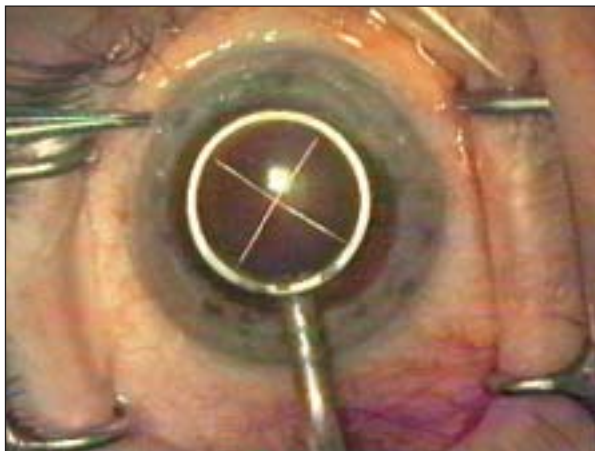


Figure 1. Dr. Wallace created a capsulotomy diameter mark. He then performed the anterior capsulotomy just inside this indentation.

"Because the anterior capsulotomy dictates how the rest of the procedure will go, any steps surgeons can take to be more predictable make sense."

—R. Bruce Wallace III, MD, FACS

cornea to help gauge the size of the capsulotomy and its position. This technique allows me to be more predictable in capsular overlap, which David Apple, MD, of Salt Lake City has shown can help reduce the incidence of posterior capsular opacification with the use of square-edge IOLs.¹ To create a 5.5-mm capsulotomy, I use a 6.0-mm optic zone marker. As surgeons begin to implant accommodative IOLs, the capsulotomy size will become even more important (Figure 1).²

2. Use the soft-shell viscoelastic technique. As Steve Arshinoff, MD, of Toronto described,³ initially using a viscodispersing agent (such as Viscoat [Alcon Laboratories, Inc., Fort Worth, TX] or Vitrac [Advanced Medical Optics, Inc., Santa Ana, CA]) to coat the endothelium and then layering a cohesive viscoelastic (such as ProVisc [Alcon Laboratories, Inc.], CoEase [Advanced Medical Optics, Inc.], or Healon [Pfizer Inc., New York, NY]) between the dispersive material and the anterior capsule provide good corneal protection.

This technique also helps the surgeon to propagate the anterior capsulotomy more predictably under a less resistant viscoelastic.

3. Fixate the globe with a cyclodialysis spatula through the sideport incision. In these days of topical anesthesia, it is helpful to have some support of the globe during this important part of the procedure.

4. Use a capsular forceps. I once used a bent 25-gauge needle to perform the entire capsulotomy. After switching to topical anesthesia, however, I found that there is less predictability with this technique. Now, I recommend using a capsular forceps, particularly with the newer modifications of the Utrata forceps (Duckworth & Kent Ltd., Hertfordshire, England).

5. If the tear begins to radiate outward, stop and add viscoelastic. When there is increased vitreous pressure and a shallowing of the anterior chamber, radiating tears can extend posteriorly, thereby making it difficult to complete the capsulorhexis. In such an instance, the surgeon should not only add viscoelastic but also look for other reasons for a shallowing of the anterior chamber such as a tight lid speculum.

As we transition to bimanual phacoemulsification, we will be looking for instruments (eg, a cross-action capsular forceps) that will allow us to perform the procedure through smaller incisions. No matter what new instrumentation or surgical techniques become popular, the anterior capsulotomy will continue to be an important part of cataract and lens-based refractive procedures.

PAUL KOCH, MD

The capsulotomy that starts easily will most likely continue easily. I begin by ensuring that the anterior capsule is flat before I puncture it. I inject the viscoelastic before entering the eye. Sometimes, when I introduce the capsulotomy forceps, however, some viscoelastic escapes, and the capsule becomes convex. In such instances, I refill the anterior chamber to flatten the capsule before proceeding.

"The capsulotomy that starts easily will most likely continue easily. I begin by ensuring that the anterior capsule is flat before I puncture it."

—Paul Koch, MD

I use the capsulotomy forceps alone for every step of the capsulorhexis. I begin by poking the tips of the forceps into the geometric center of the capsule and puncture it there. By pulling the forceps back toward me, I open a wedge of capsule defined by two diverging linear capsular tears, just like the original Christmas tree capsulotomy. The blunt sides of the tips drag the capsule, rather than cut it in a straight line. Once I pull the tips back 2 mm or so, I push them off to my right. This maneuver converts the straight tear of the wedge into a curve to the right, thereby beginning the curvature that will continue all the way around.

In the case of a pressurized white cataract, I tamponade the capsule with Healon5 (Pfizer Inc.) to prevent an explosion of cortex that can split the capsule in all directions. If the lens is white or very dark, I stain the anterior capsule with trypan blue, which I obtain from a commercial custom-compounding laboratory.

STEVEN DEWEY, MD

Preparation is the key to the consistent performance of a 5-mm centered capsulorhexis. First, recognize that the chamber stability created by dispersive viscoelastics such as Vitrax and Viscoat is far superior to that with cohesive viscoelastics, and it provides some viscomydriasis for smaller pupils. Second, recall that the anterior segment size and pupil dilation vary among individuals. Just as ophthalmologists observe the rim area in a glaucoma patient as opposed to the cup, if you can consistently recognize the variable size of the pupil and the anterior segment, then sizing the capsulorhexis will become second nature. Consistent case-to-case magnification with the operating microscope and an external marker (such as a Fine Thornton fixation ring [8-15221; Rhein Medical Inc., Tampa, FL]) will assist you in recognizing these disparities in size, as will Dr. Wallace's aforementioned technique with an optical zone marker.

*"If you can consistently recognize the variable size of the pupil and the anterior segment, then sizing the capsulorhexis will become second nature."
—Steven Dewey, MD*

The unanticipated problem that I encounter most frequently is a regional loss of the red reflex that is sufficient to eliminate my visualization of the capsular flap. This problem is usually due to a dense cortical spoke, almost always located in the inferonasal quadrant and approximately halfway into the capsulorhexis. A light pipe placed at the limbus and directed across the surface of the capsule will provide enough contrast for me to find and grasp the lost edge of the capsulorhexis with a forceps. Increasing magnification and turning off the microscope light will improve the effect of the tangential illumination. If a light pipe is in short supply, or several tense minutes away, then I recommend using a FLX-Lite (Linvatec Corporation, Largo, FL). Although the FLX-Lite is not as well directed as a light pipe, the device is small, sterile, and flexible, and it will more than suffice in a pinch.

BROCK K. BAKWELL, MD, FACS

The correct sizing of the anterior capsulorhexis (such that 0.50 to 0.75 mm of overlap exists on the optic for 360°) is important for a number of reasons: (1) to prevent the anterior displacement of the lens and an unexpected myopic outcome; (2) to help prevent posterior

capsular opacification; (3) to allow for an easy lens exchange in the bag if the IOL power is incorrect; (4) to allow sufficient room for easy phacoemulsification; and (5) to help prevent phimosis. In my opinion, the capsulorhexis is the most important part of the cataract operation.

"If you do not measure the pupil, it is easy to make the rhexis too large in an eye with a large pupil or too small in an eye with a small pupil."

—Brock K. Bakewell, MD, FACS

In order to correctly size the rhexis, prior to beginning the operation, I have found it helpful to measure the dilated pupil with either a caliper or the pupil aperture holes of a Rosenbaum card. If you do not measure the pupil, it is easy to make the rhexis too large in an eye with a large pupil or too small in an eye with a small pupil. In reality, the actual pupil size is smaller than that measured due to the magnification of the cornea. Relatively, however, if a pupil measures 9 mm, then I know I must leave approximately 2 mm between the edge of the pupil and the edge of the rhexis to create a 5-mm rhexis (because the IOL's optic centers slightly nasally and superior to the geometric center of the eye, the superior and nasal edge of the rhexis is closer to the pupillary margin, and the lateral and inferior edge of the rhexis is farther away).

I use a bent 25-gauge needle to initiate the rhexis with a central puncture of the anterior capsule and extend the puncture trough peripherally by approximately 2 mm. With Utrata forceps, I extend the tear in a clockwise fashion and regrasp at least every 90°. When creating the rhexis, I think about how far the rhexis edge needs to be from the edge of the pupil in order to create a 5-mm round opening.

LOUIS D. "SKIP" NICHAMIN, MD

When faced with a challenging capsulorhexis, particularly one associated with a shallow anterior chamber, my preference is to perform the rhexis, at least in part, with a cystotome attached to a viscoelastic syringe. By so doing, I can immediately re-deepen the anterior chamber without removing instrumentation. As ophthalmologists have long recognized, the main cause for an errant capsular tear is a shallowing of the anterior chamber, with a subsequent excursion of the rhexis peripherally along the path of least resistance. Imme-

diately and, at times, frequently re-deepening the anterior chamber can prevent this problem.

“When creating the rhexis, the surgeon may utilize the OVD as a ‘second hand’ in order to direct the leading capsular flap into an optimal direction and position.”

—*Louis D. “Skip” Nichamin, MD*

In addition, when creating the rhexis, the surgeon may utilize the OVD as a “second hand” in order to direct the leading capsular flap into an optimal direction and position. Although I do not use Healon5 routinely, this OVD is perhaps the best agent to prevent such a lost or “wrap-around” anterior capsular tear. Finally, one must always be cognizant of the position of both the cystotome and the capsulorhexis forceps within the corneal tunnel as well as avoid unnecessary pressure on the wound, a force that can lead to a leakage of the viscoelastic agent and a shallowing of the chamber. ■

William J. Fishkind, MD, FACS, is Co-director of Fishkind and Bakewell Eye Care and Surgery Center in Tucson, Arizona, and Clinical Professor of Ophthalmology at the University of Utah in Salt Lake City. He is a consultant for Advanced Medical Optics, Inc., but does not hold a financial interest in any product mentioned herein. Dr. Fishkind may be reached at (520) 293-6740; wfishkind@earthlink.net.

Brock K. Bakewell, MD, FACS, is Clinical Assistant Professor at the University of Utah in Salt Lake City



and Codirector of Fishkind and Bakewell Eye Care and Surgery Center in Tucson, Arizona. He does not hold a financial interest in any product or company mentioned herein. Dr. Bakewell may be reached at (520) 293-6740; eyemanaz@aol.com.

Steven Dewey, MD, practices in Colorado Springs, Colorado, with the Colorado Springs Health Partners. He does not hold a financial interest in any product or company mentioned herein. Dr. Dewey may be reached at (719) 475-7700; sdewey@cshp.net.



Paul Koch, MD, is in private practice at Koch Eye Associates in Warwick, Rhode Island. He does not hold a financial interest in any product or company mentioned herein. Dr. Koch may be reached at (401) 738-4800; paulkoch@kocheye.com.



Louis D. "Skip" Nichamin, MD, is Medical Director of the Laurel Eye Clinic in Brookville, Pennsylvania. He does not hold a financial interest in any product or company mentioned herein. Dr. Nichamin may be reached at (814) 849-8344; ldnichamin@aol.com.



R. Bruce Wallace III, MD, FACS, is Director of Wallace Eye Surgery in Alexandria, Louisiana; Clinical Professor of Ophthalmology at Louisiana State University in New Orleans; and Assistant Clinical Professor of Ophthalmology at Tulane University in New Orleans. He is a paid consultant for Advanced Medical Optics, Inc. Dr. Wallace may be reached at (318) 448-4488; rbw123@aol.com.



1. Apple D, Peng Q, Visessook N, et al. Eradication of posterior capsule opacification: documentation of a marked decrease in Nd:YAG laser posterior capsulotomy rates noted in an analysis of 5416 pseudophakic human eyes obtained postmortem. *Ophthalmology*. 2001;108:505-518.
2. Wallace RB. Capsulotomy diameter mark. *J Cataract Refract Surg*. 2003;29:1866-1868.
3. Arshinoff SA. Dispersive-cohesive viscoelastic soft shell technique. *J Cataract Refract Surg*. 1999;25:167-173.